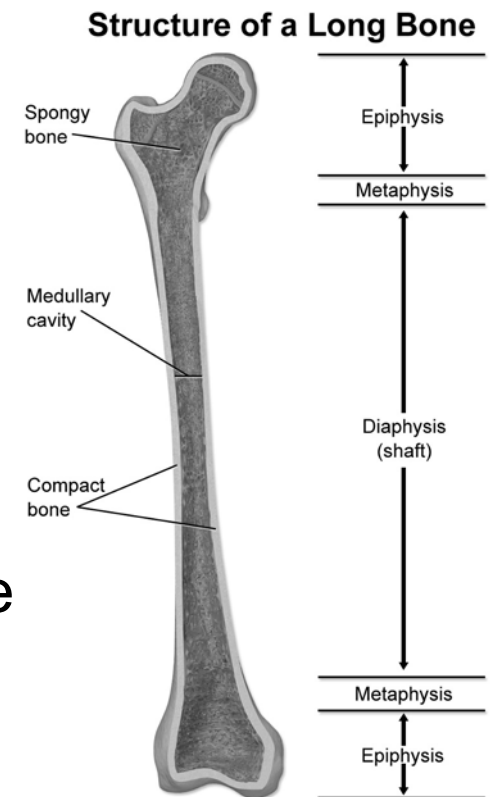


Bone and Joint Pathology For Second Year Dental Students

Most of the images used were carefully selected from the web

Types of Bone

- Cortical bone: defines shape
- Cancellous bone (spongy): marrow bone
 - Mandible, maxilla
 - End of long bones in the medullary canal
- Epiphysis
 - From subarticular plate to epiphyseal cartilage
- Metaphysis
 - Area between epiphyseal plate to the area where bone develops its funnel or flute shape
- Diaphysis
 - Body of bone, between metaphyses

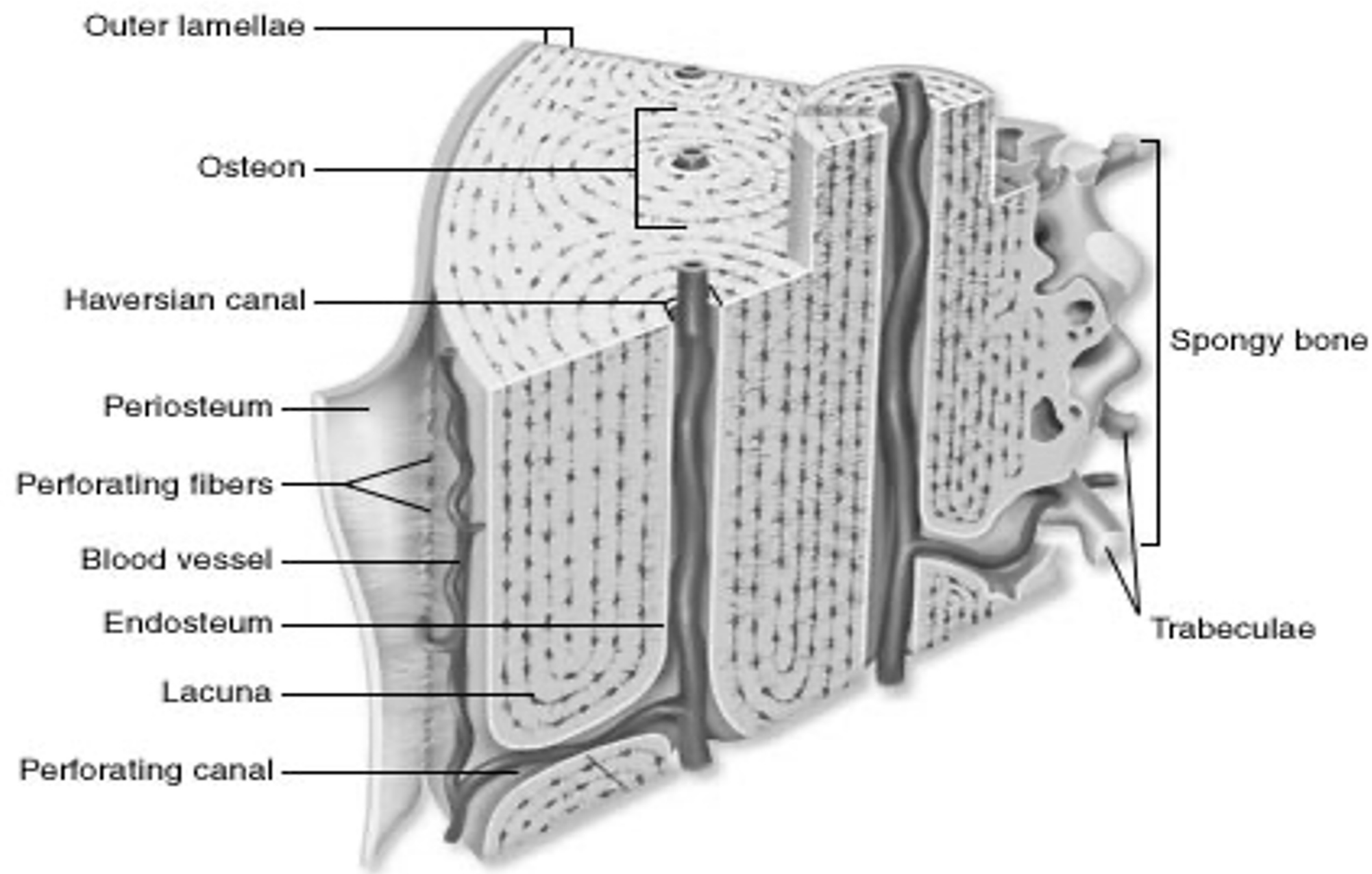


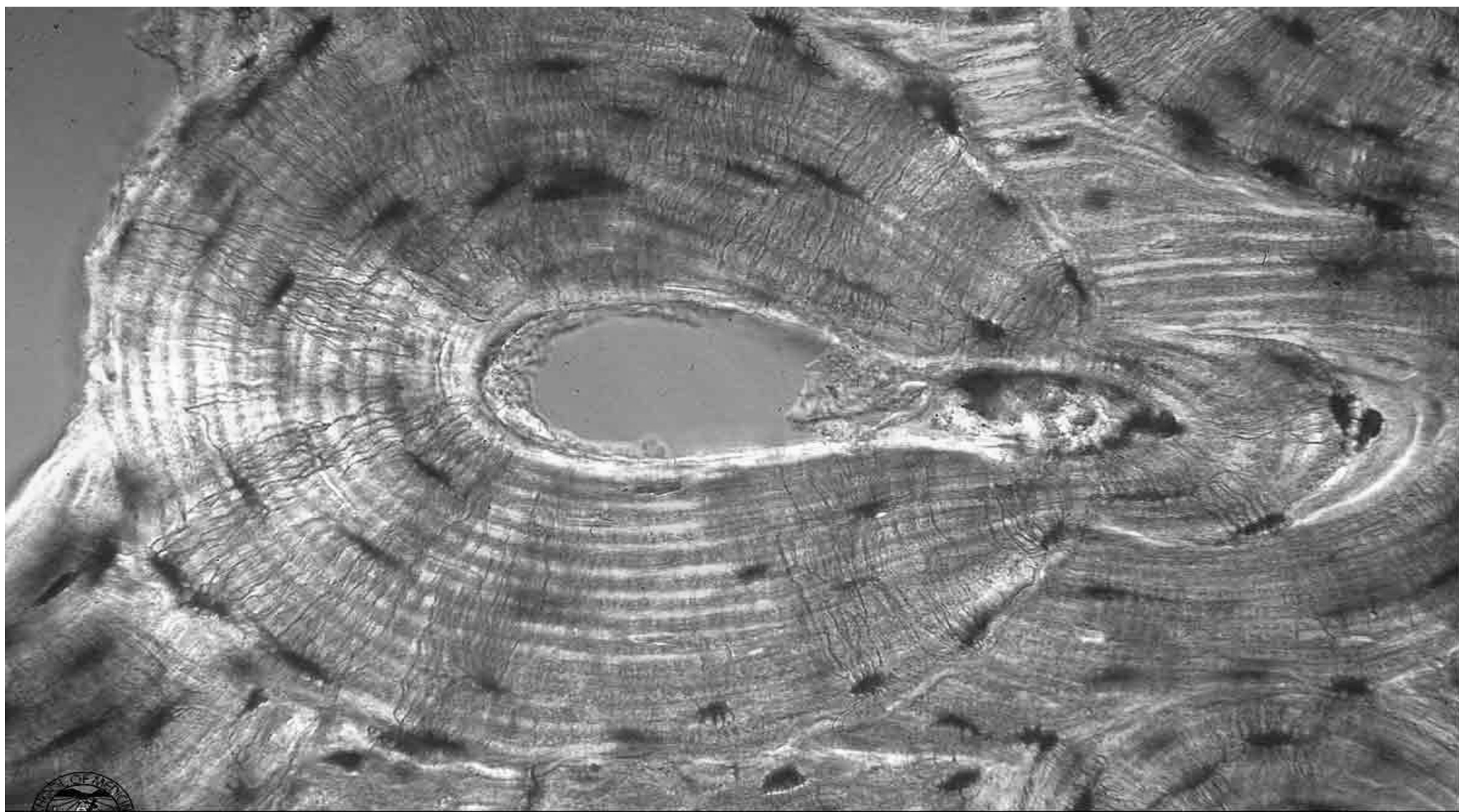
Types of Bone

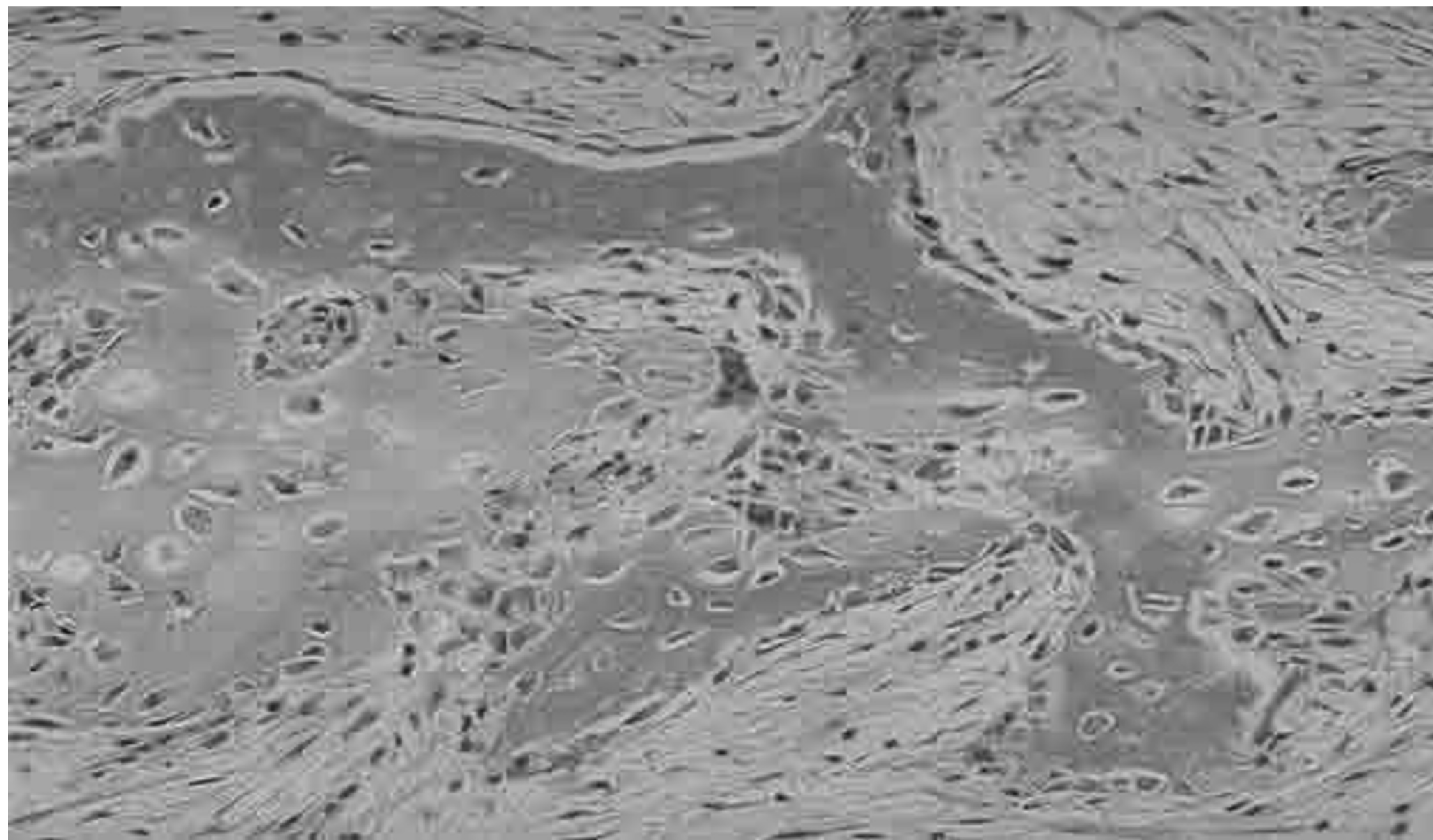
- Lamellar
 - Forms the adult skeleton
 - // arrangement of collagen fibers
 - Few osteocytes
 - Uniform osteocytes in lacunae // to long axis of collagen fibers
- Woven
 - Irregular
 - Many osteocytes of various size and shape
 - In adults signifies always a pathologic condition

Cells

- Osteoblasts
 - Produce the protein
 - Osteoid
- Osteocyte
 - Osteoblast within bone in a lacuna
- Osteoclast
 - Multinucleated
 - Resorbs bone
 - Howship's lacunae





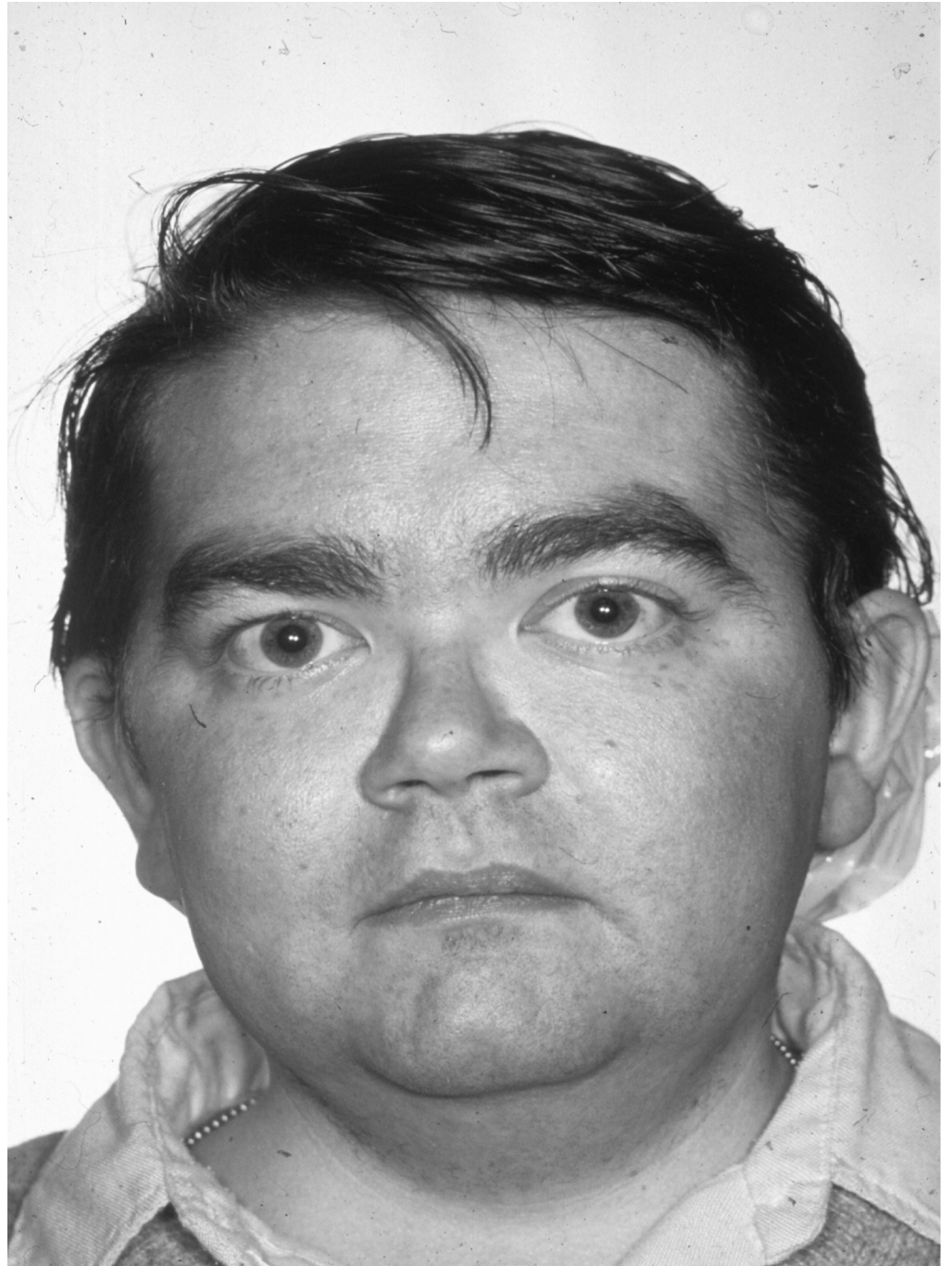


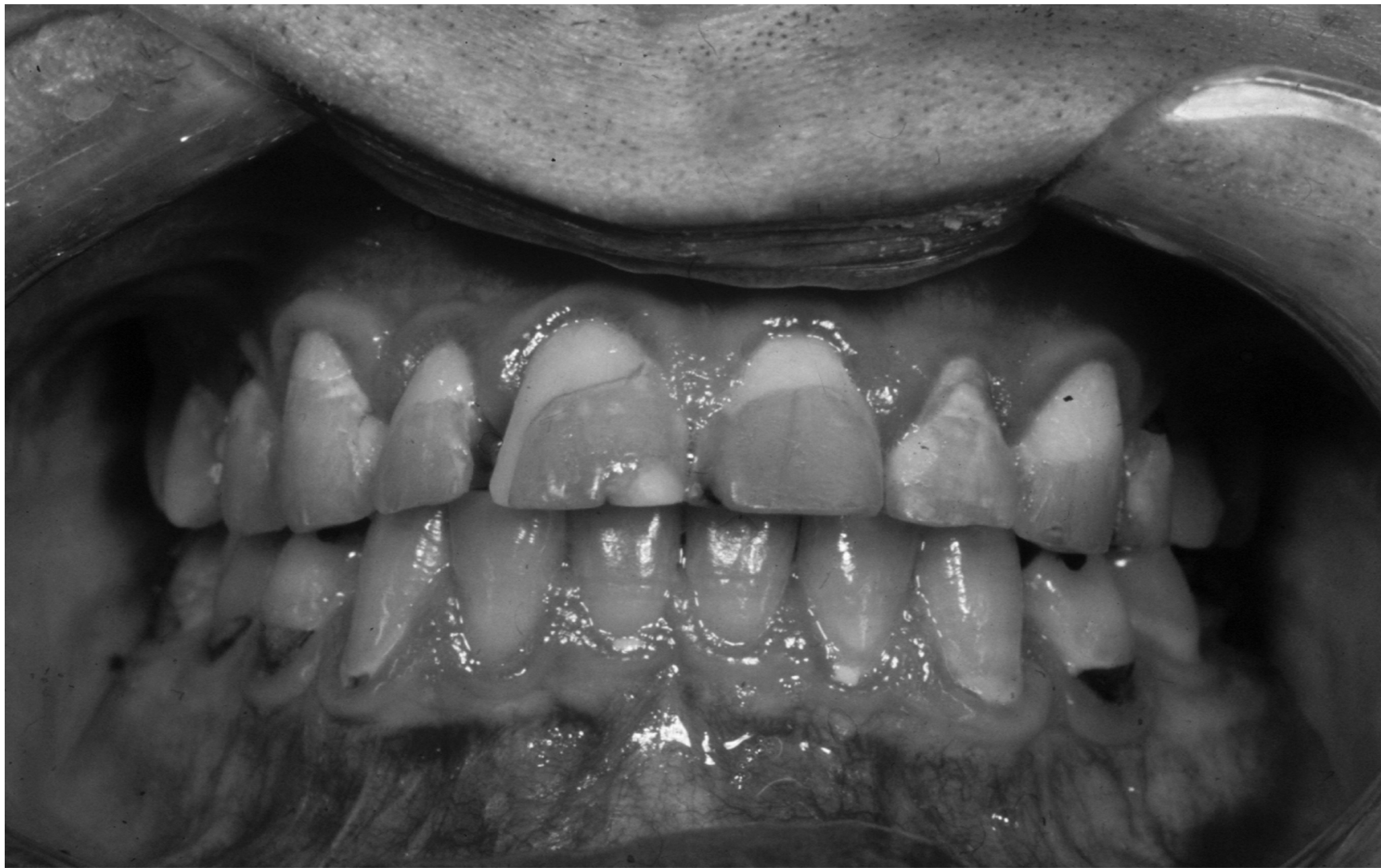
Bone Lesions

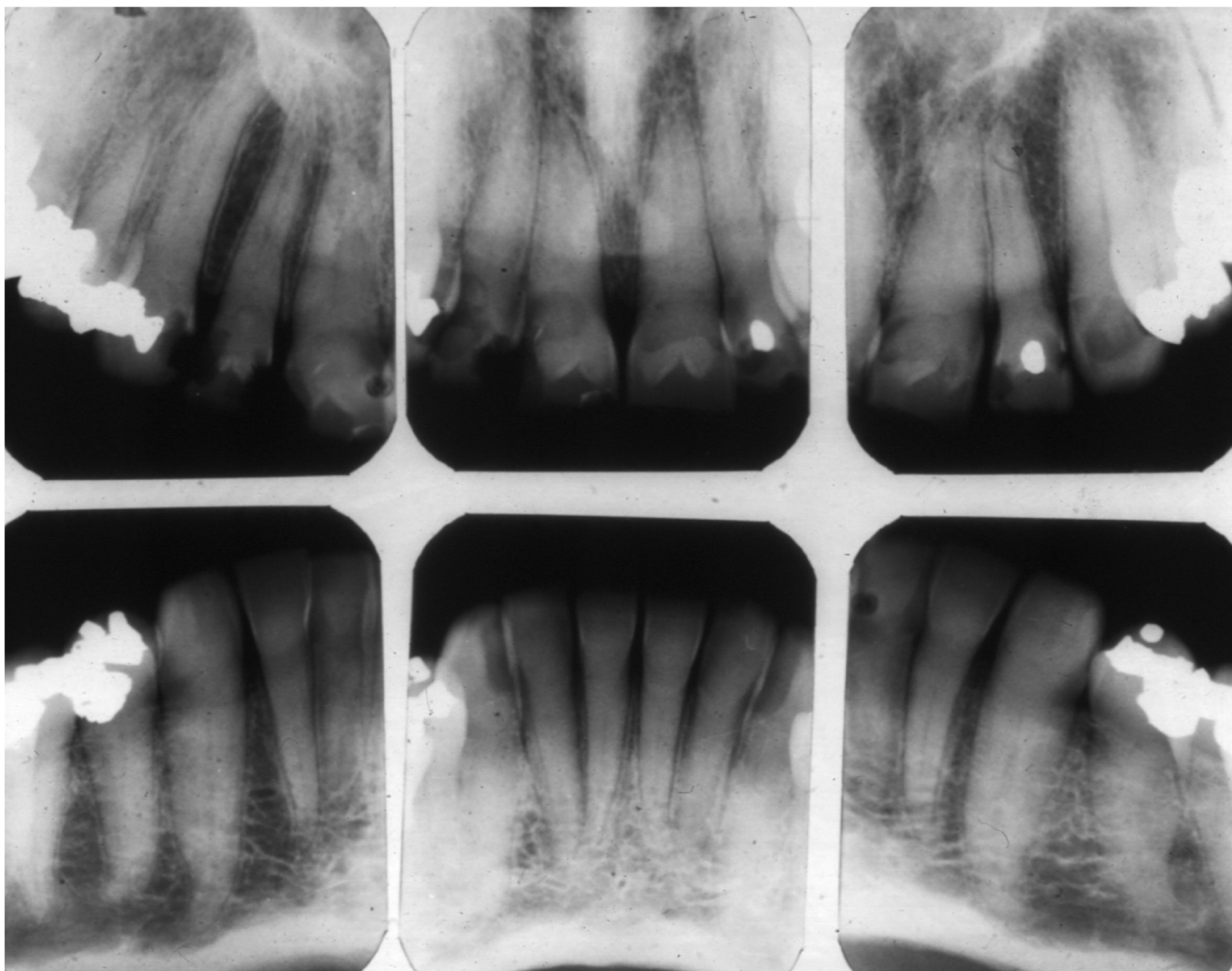
- **Congenital**
Dysostoses, Aplasia, Supernumerary, Dysplasias
- **Hereditary**
Osteogenesis Imperfecta, Achondroplasia, Osteopetrosis
- **Inflammatory**
Osteomyelitis, Fracture*
- **Metabolic**
Osteoporosis, Rickets & Osteomalacia, Hyperparathyroidism
- **Neoplasms**
Osteoma, osteochondroma, osteosarcoma, chondrosarcoma, Ewing's sarcoma etc.
- **Miscellaneous**
Osteonecrosis, benign fibro-osseous lesions

Hereditary and Congenital Diseases

- Osteogenesis imperfecta (“brittle bone disease”)
 - Many types
 - Mutations of collagen type I; $\alpha 1$ & $\alpha 2$ chains
 - Type I have normal life-span
 - Inactivation of one allele of COL1A1 gene that results in a reduced amount of normal type I collagen
 - Type II is fatal
 - Dominant negative (antimorphic) mutation in the severe cases; disastrous phenotype because the product acts antagonistically to the wild type
 - Multiple fractures (starting in utero)
 - Blue sclera
 - Decreased collagen; underlying choroid (vascular layer) visible
 - Dental findings: Dentinogenesis imperfecta
 - Hearing loss (conductive)






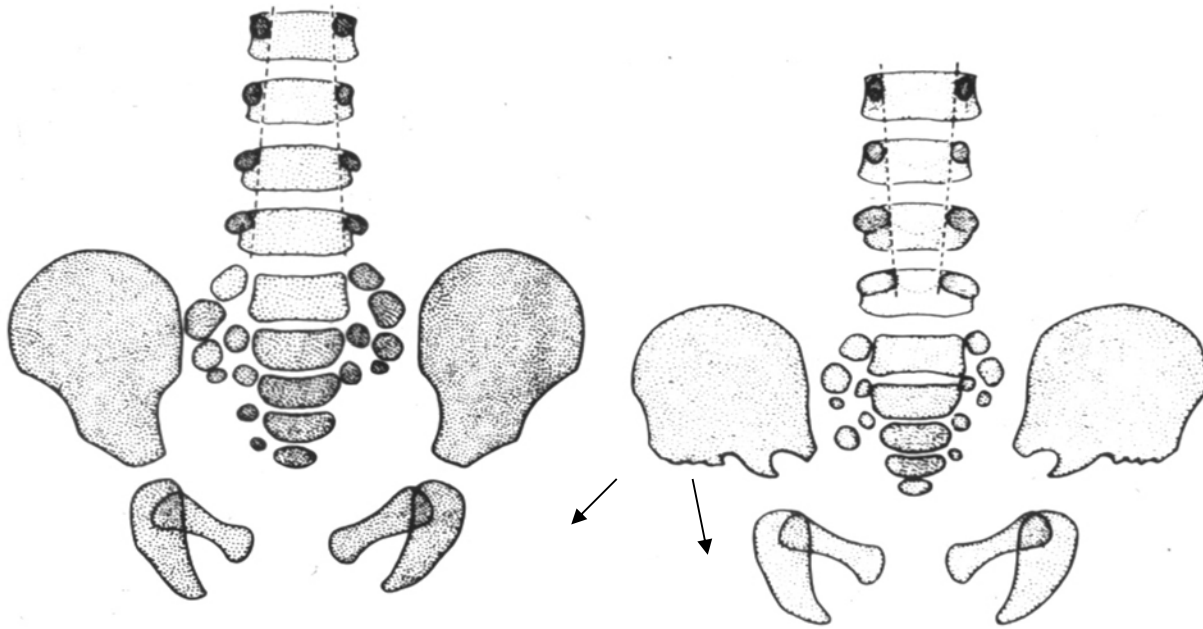


Hereditary and Congenital Diseases

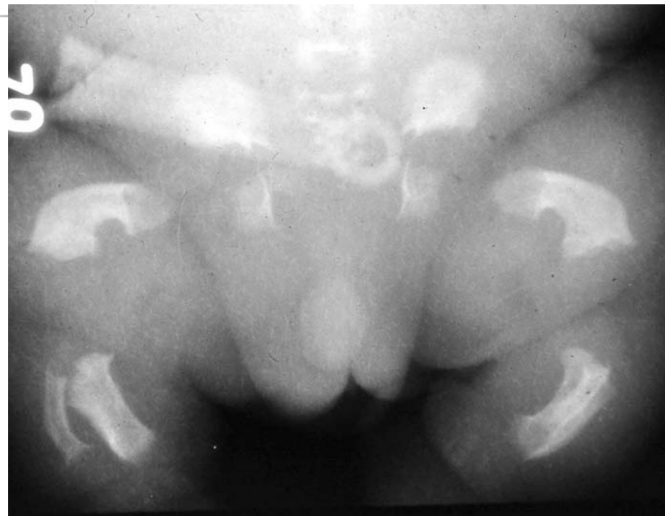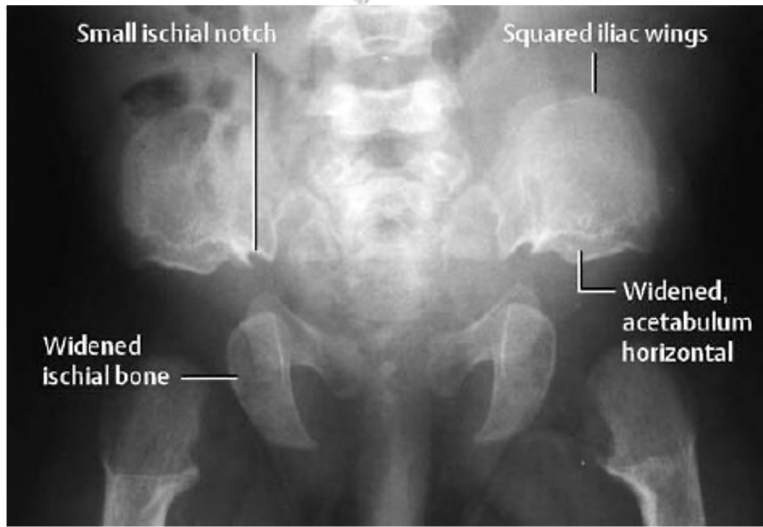
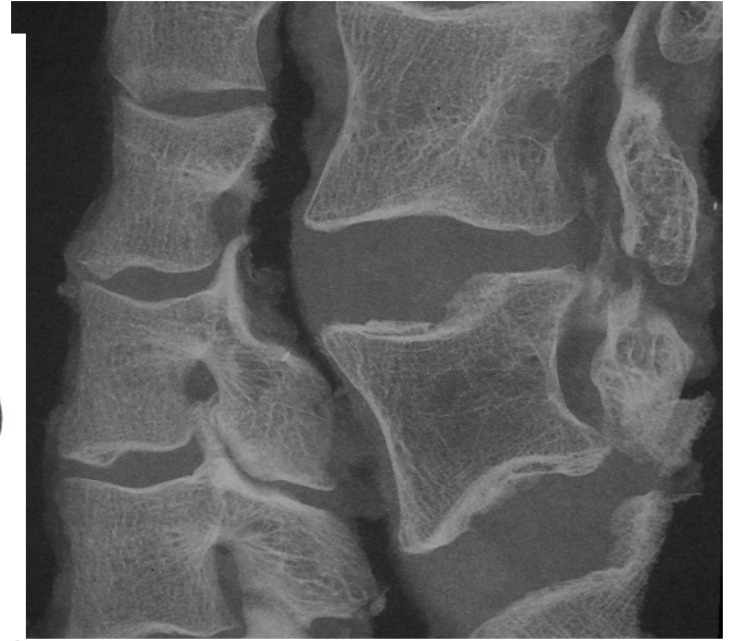
- Achondroplasia* (Major cause of dwarfism)
 - FGFR3 mutation
 - Constitutive activation; inhibition of chondrocyte proliferation
 - Thanatophoric dwarfism (missense)
 - Absence or attenuation of zone of proliferative cartilage
 - Epiphyseal disorder (plate closes prematurely preventing bone growth; affects endochondral ossification)
 - AD, 80% new mutations
 - Normal mentation and average life span
 - Head and torso are normal
 - Kypho(anterior-posterior)scoliosis(lateral curvature)
 - Cor pulmonale
 - (Right ventricular hypertrophy ← respiratory cause)
 - Hip problems



Acetabulum Deformity



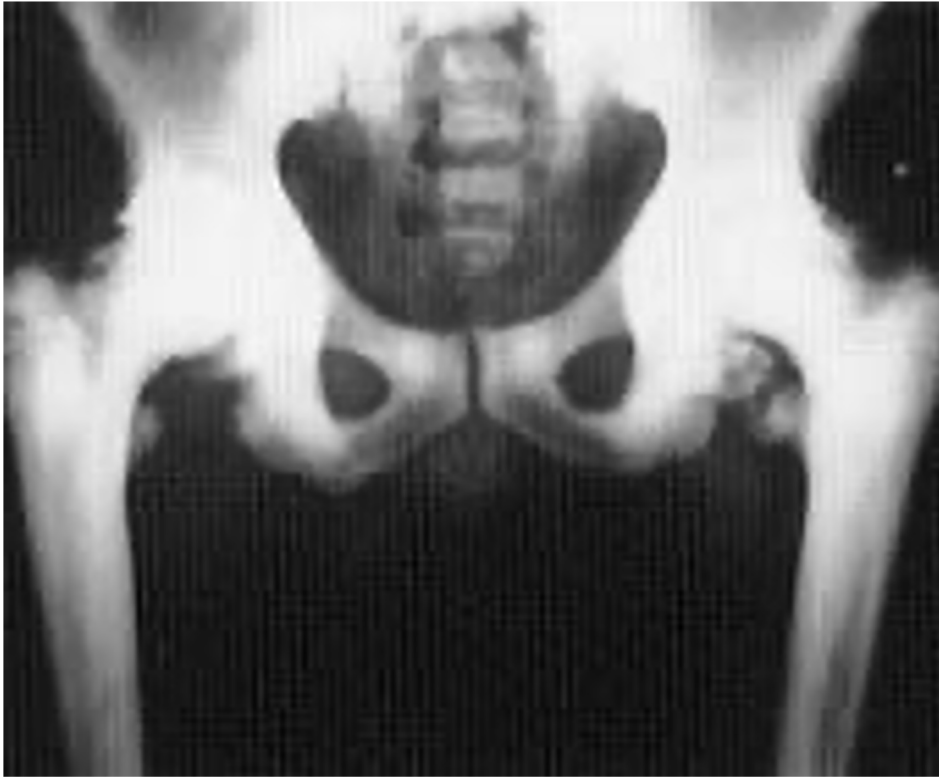Narrowing of interpedicular distance



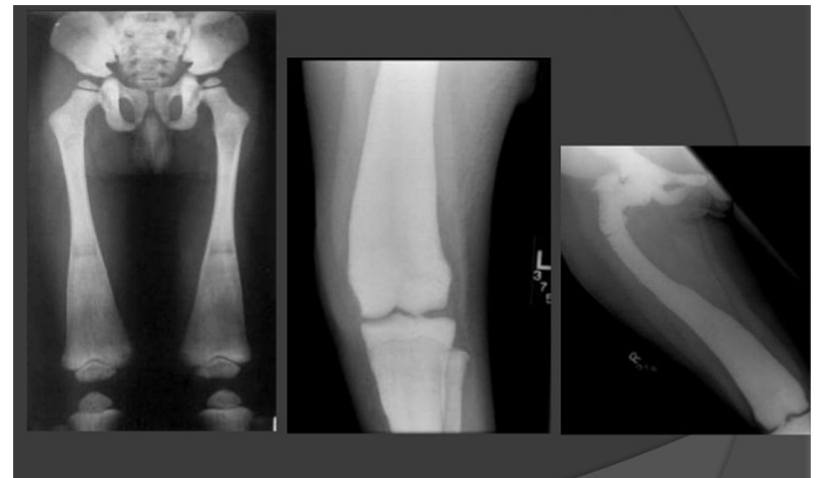Images found in the web

Hereditary and Congenital Diseases

- Osteopetrosis
 - Reduced osteoclast –mediated bone resorption
 - Defective bone remodelling, specifically reduced bone demineralization
 - AR;AD
 - Abnormal dense bone (marble or stone bone)
 - Unsound, brittle bone
 - AR: Severe form, anemia, nerve entrapment, hydrocephalus, infections, fractures
 - AD: Milder
 - Extramedullary hematopoiesis
 - Wider metaphyseal and diaphyseal areas (Erlenmeyer flask)
 - Extremely irregular bone with cartilage core



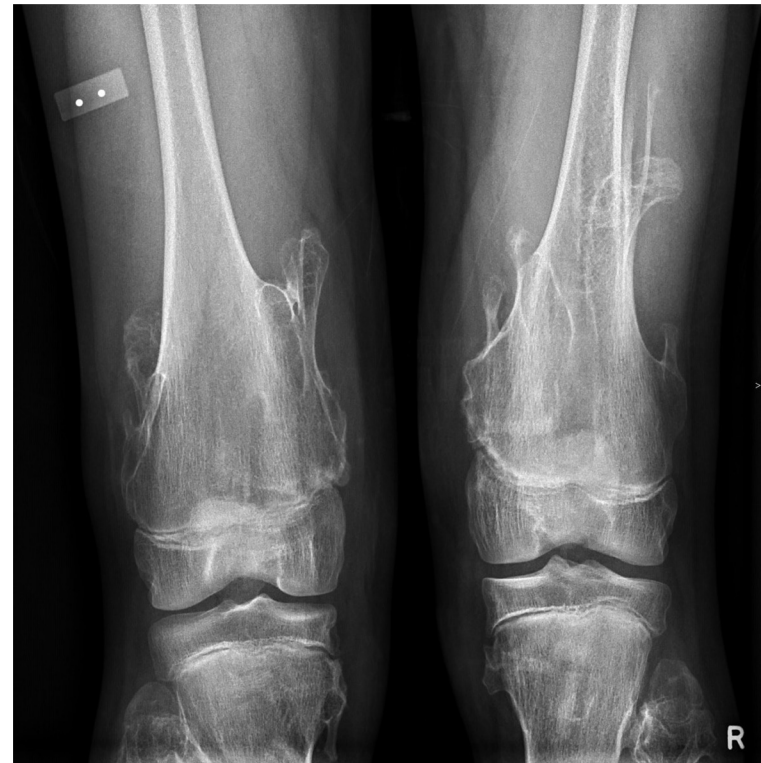marble or stone bone



Erlenmeyer flask

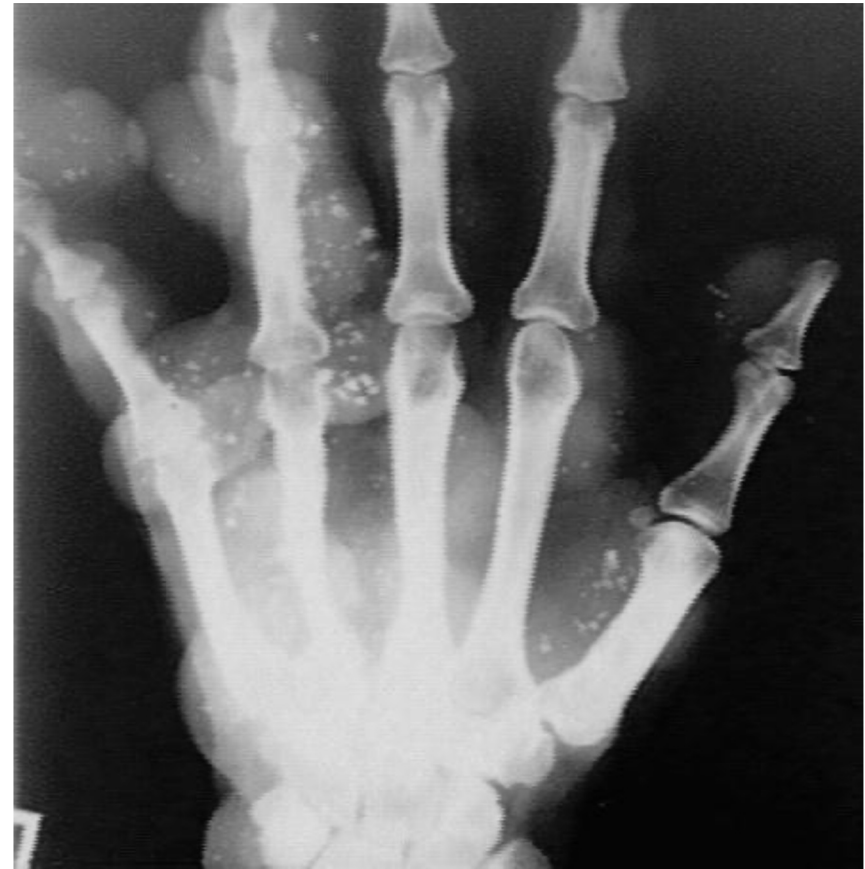Hereditary and Congenital Diseases

- **Hereditary multiple osteochondromatosis**
- **(AKA Hereditary multiple exostoses)**
 - AD, men predominance, women can transmit
 - Multiple osteochondromas
 - Abnormality of epiphyseal plate (cartilage grows laterally to the soft tissue), metaphyseal lesions
 - Metacarpals, wrists, knees, unequal length of extremities
 - Long term increased risk for chondrosarcoma



Hereditary and Congenital Diseases

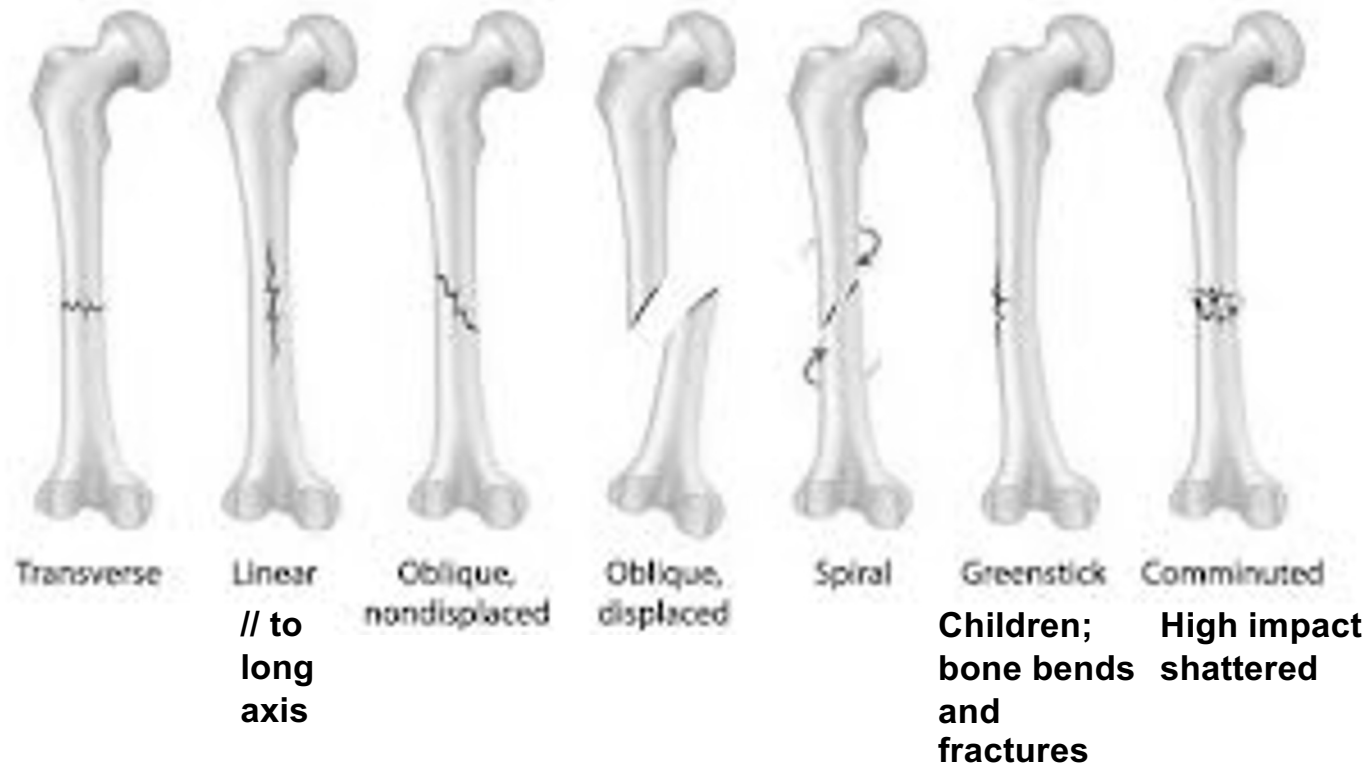
- **Ollier's disease**
 - Start at the metaphysis and become diaphyseal
 - Multiple enchondromas
 - Mature hyaline cartilage within bone
 - Small bones of hands
 - Chondrosarcoma in 30-50% of cases



Inflammatory and Non-Inflammatory (Non-neoplastic) Disorders

- Fracture: discontinuity of bone
 - Complete or incomplete
 - Closed or Compound (skin)
 - Comminuted (splintered bone); displaced
 - Pathologic (tumor); stress fracture (result of chronic injury; repeated trauma)
- Three phases
 - Inflammatory
 - Reparative
 - Remodeling

Types of Bone Fractures



Inflammatory Phase

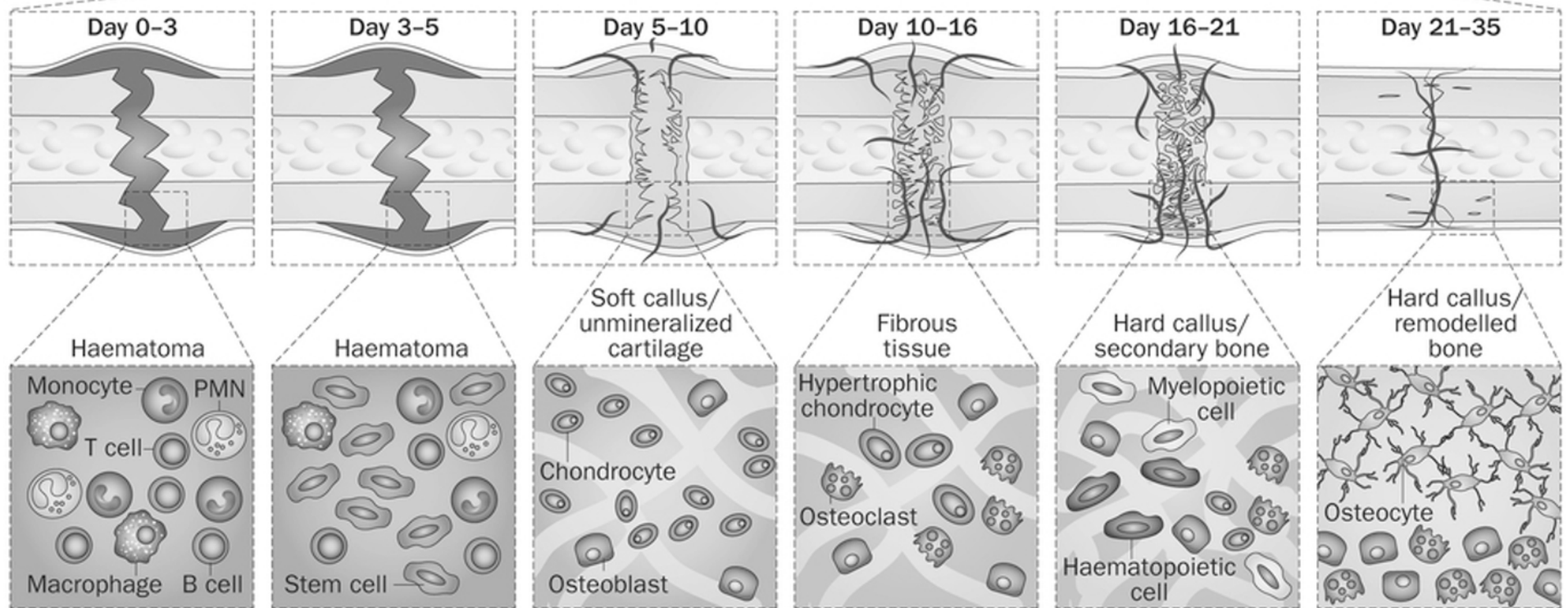
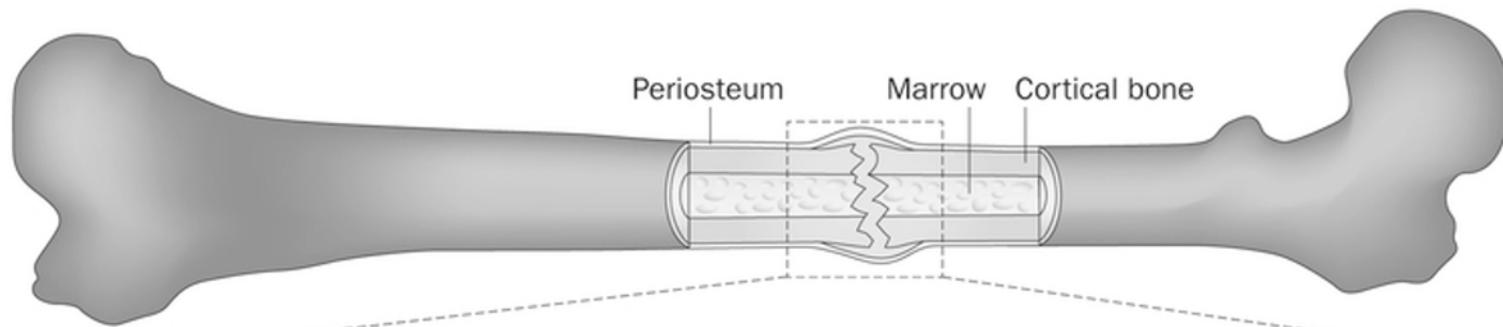
- First week
- Rupture of blood vessels in the periosteum and soft tissues
- Bone necrosis at the site
- Neovascularization peripheral to blood clot
- Neutrophils, macrophages and other mononuclear cells
- Clot organization and early fibrosis
- Callus formation
 - Woven bone, some cartilage (eventually resorbed)

Reparative Phase

- Months
- Proliferating fibroblasts and osteoblasts
- Blood clot resorption
- Callus bridge

Remodeling Phase

- Several weeks - years
- Callus has sealed the bone ends
- Remodeling



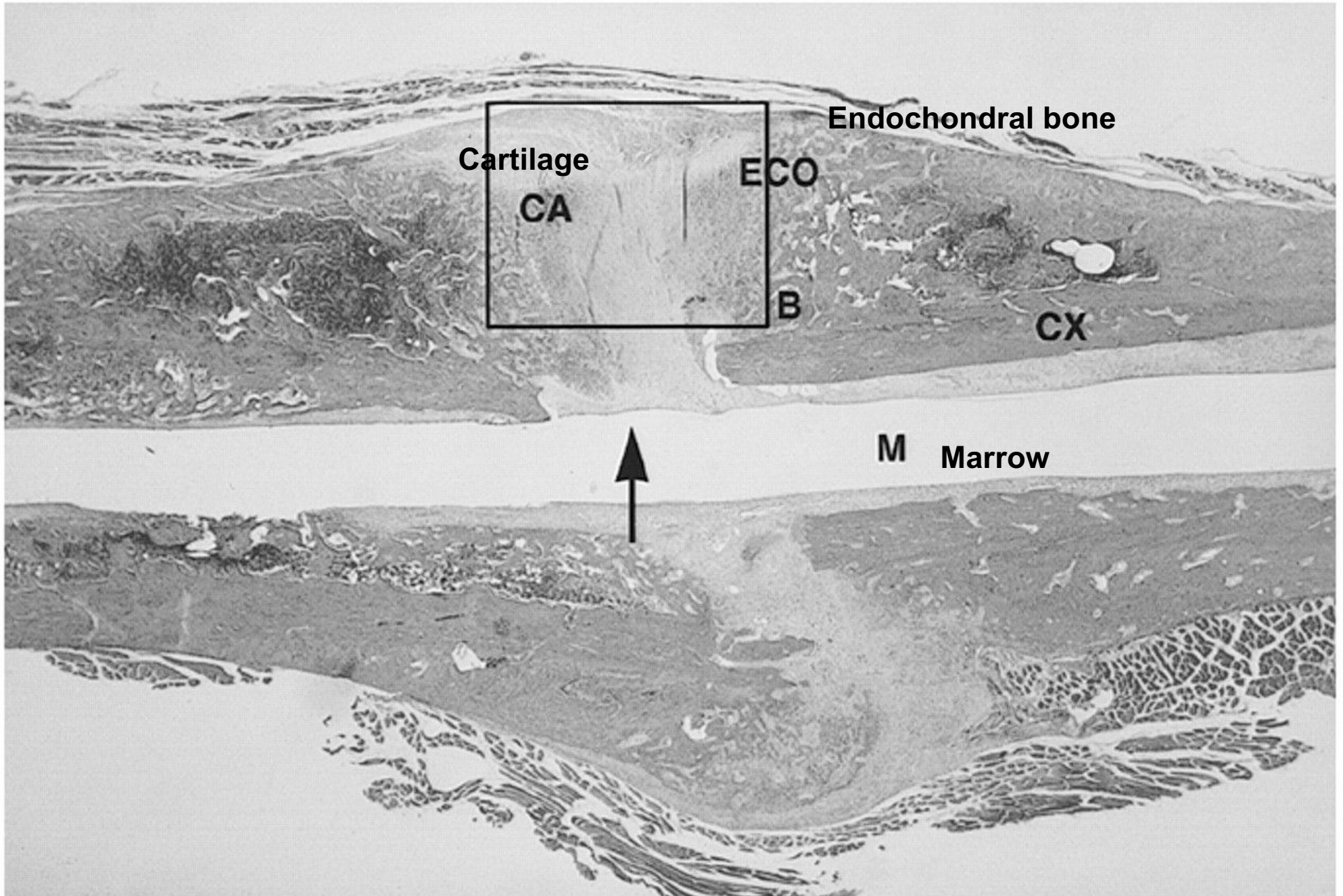
Anabolic phase

Catabolic phase

Inflammatory stage

Endochondral stage

Coupled remodelling stage



Disruptions of remodelling

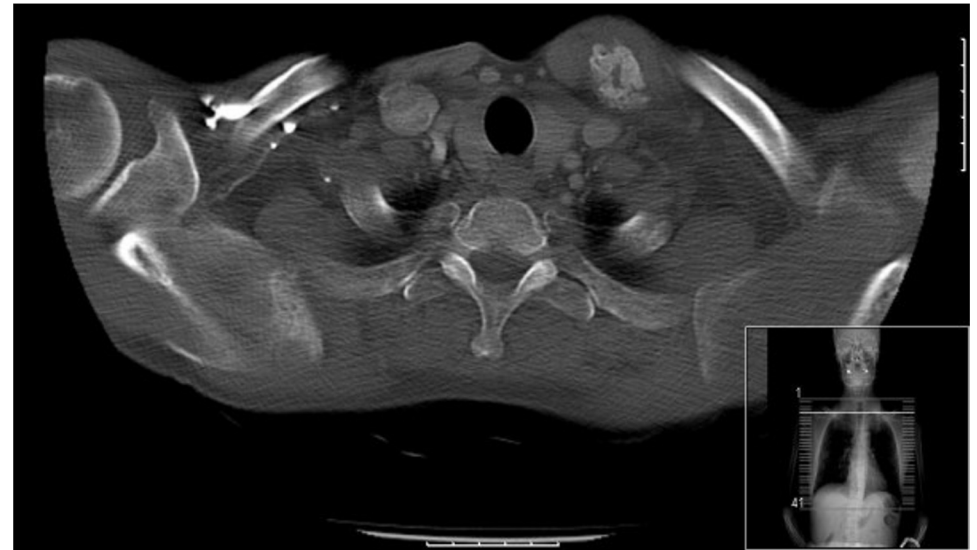
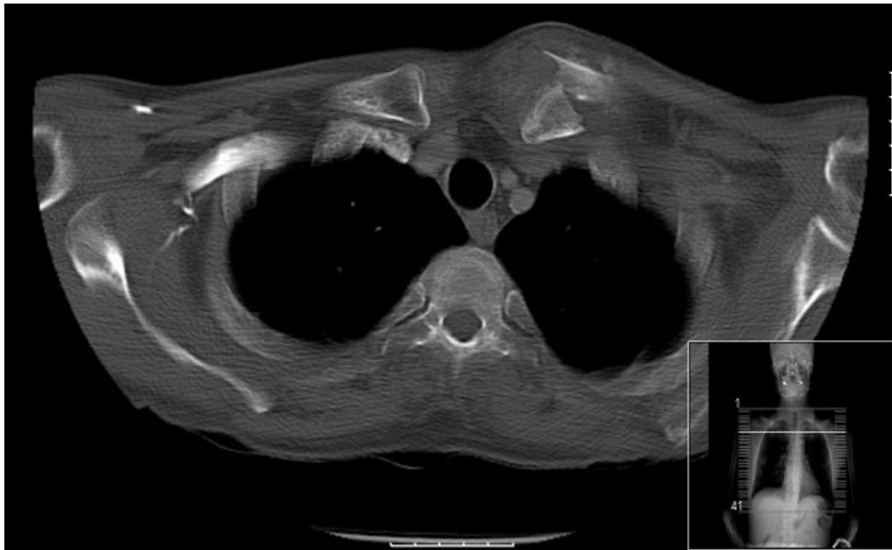
- Deformity ← displacement
- Fibrous remodeling
- Pseudoarthrosis
- Infection
- Impairment because of lack in Ca, P, vit.D, systemic infection, medications, diabetes, etc.

Osteonecrosis

- Avascular, aseptic
- Ischemic death of bone and marrow in absence of infection
 - Trauma
 - Emboli: bone infarction
 - Systemic diseases
 - sickle cell disease, lupus, gout, metabolic diseases
 - Radiation
 - Corticosteroids
 - Site specific: head of femur, navicular bone
 - Alcoholism
 - Osteochondritis dissecans: dead piece of cartilage

Myositis Ossificans

- Formation of reactive bone in muscle as a result of injury
- Mimics neoplasm radiographically and histologically
- Lower limbs



Osteomyelitis

- Inflammation of bone caused by an infectious organism
- Staphylococcus, streptococcus, escherichia coli, neisseria gonorrhea, haemophilus influenza, salmonella (sickle cell disease)
- Direct penetration
 - Wounds, fractures, surgery
- Hematogenous
 - Bloodstream, teeth; metaphyses
 - Knee, ankle, hip

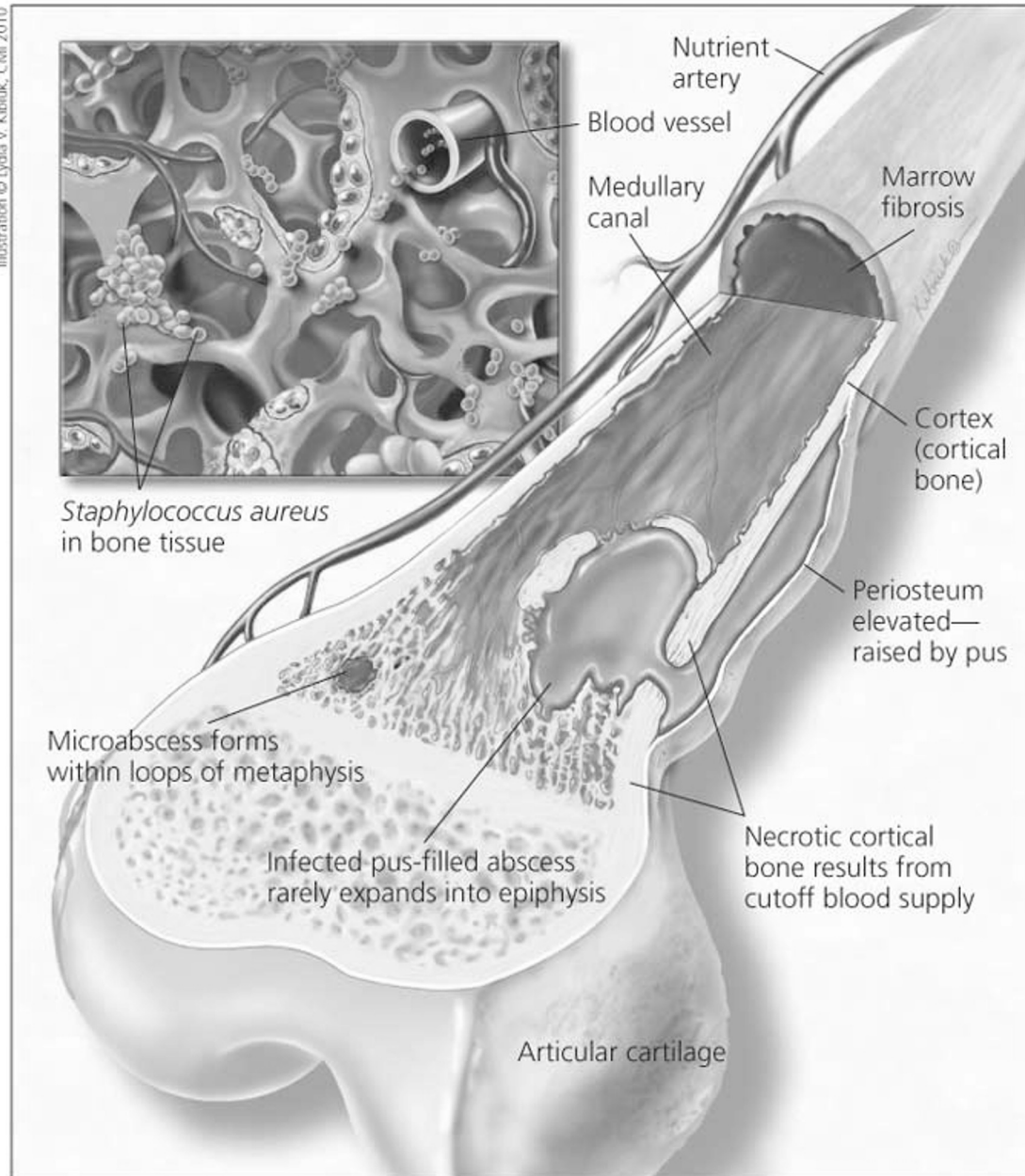
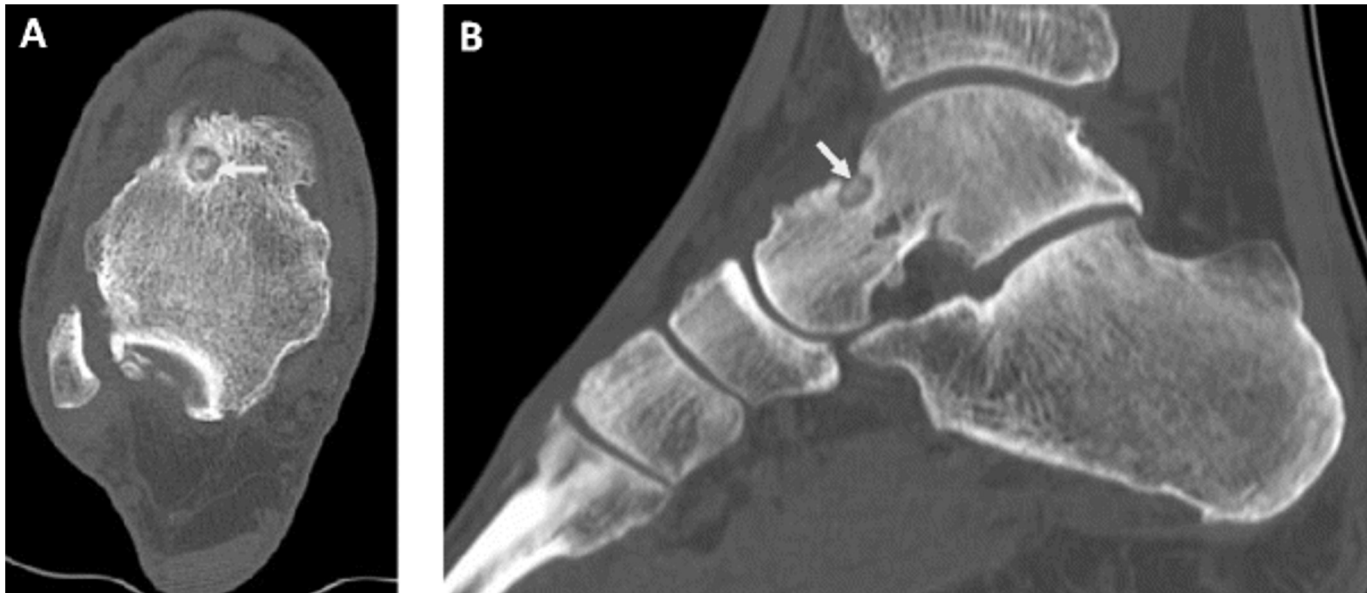


Figure 1 – This diagram shows hematogenous osteomyelitis of a tubular bone in a child.

From Baromedical

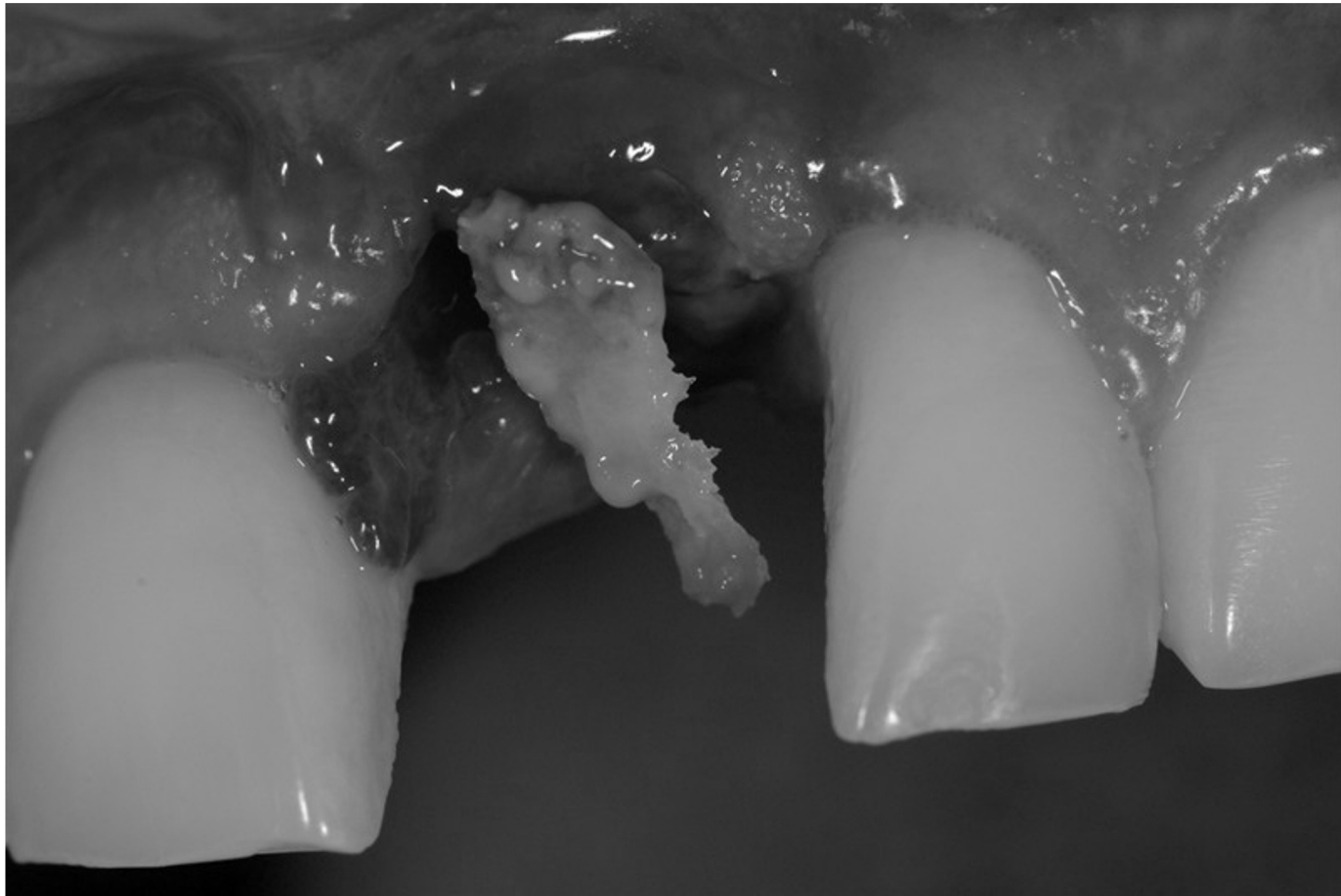
Vocabulary

- Cloaca: hole in bone during formation of the draining sinus



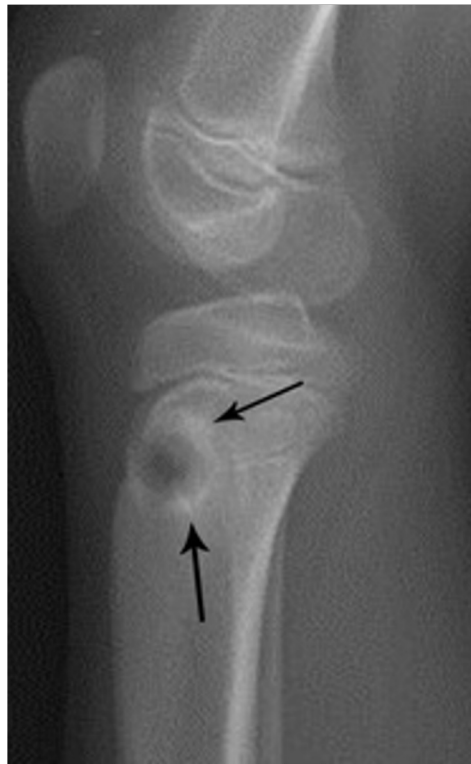Vocabulary

- Sequestrum: fragment of necrotic bone in the pus



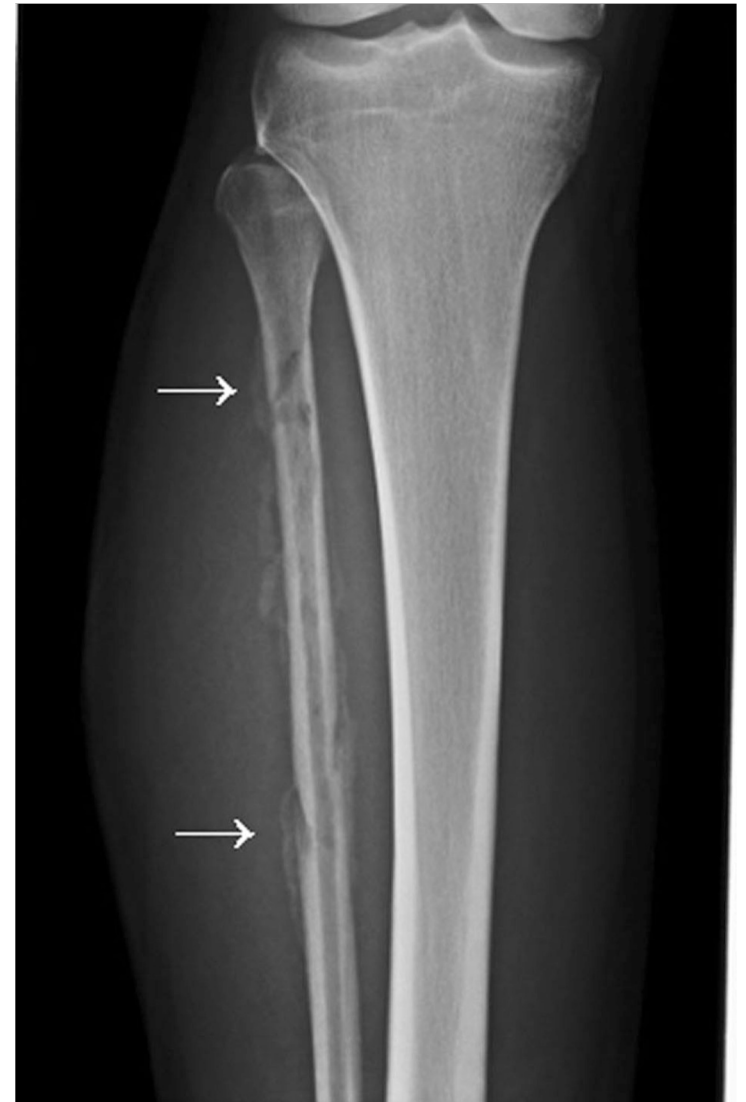Vocabulary

- Brodie abscess: reactive bone from periosteum and endosteum which surrounds and contains infection

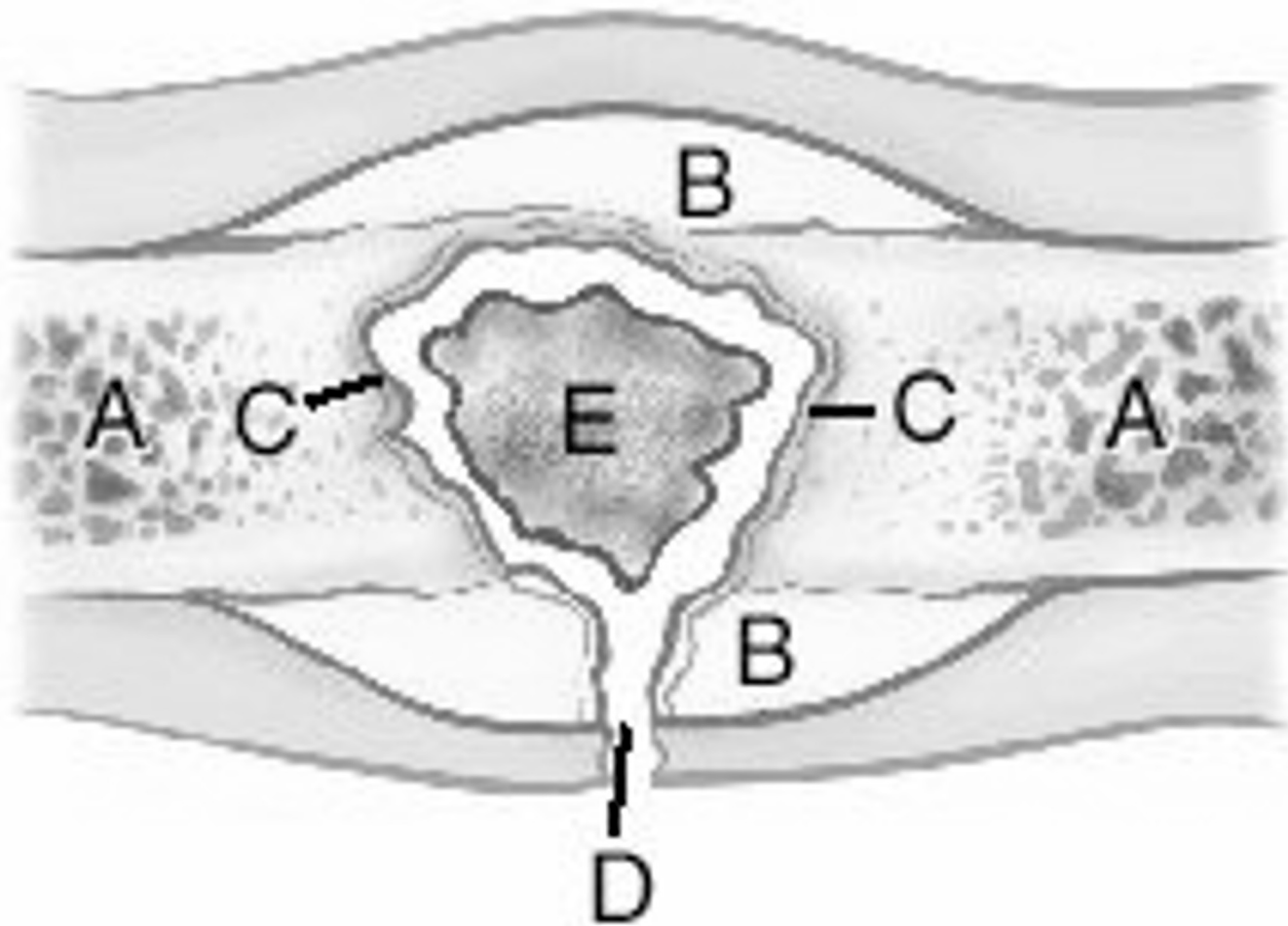


Vocabulary

- Involucrum: Periosteal new bone covering the sequestrum



A:?
B:?
C:?
D:?
E:?



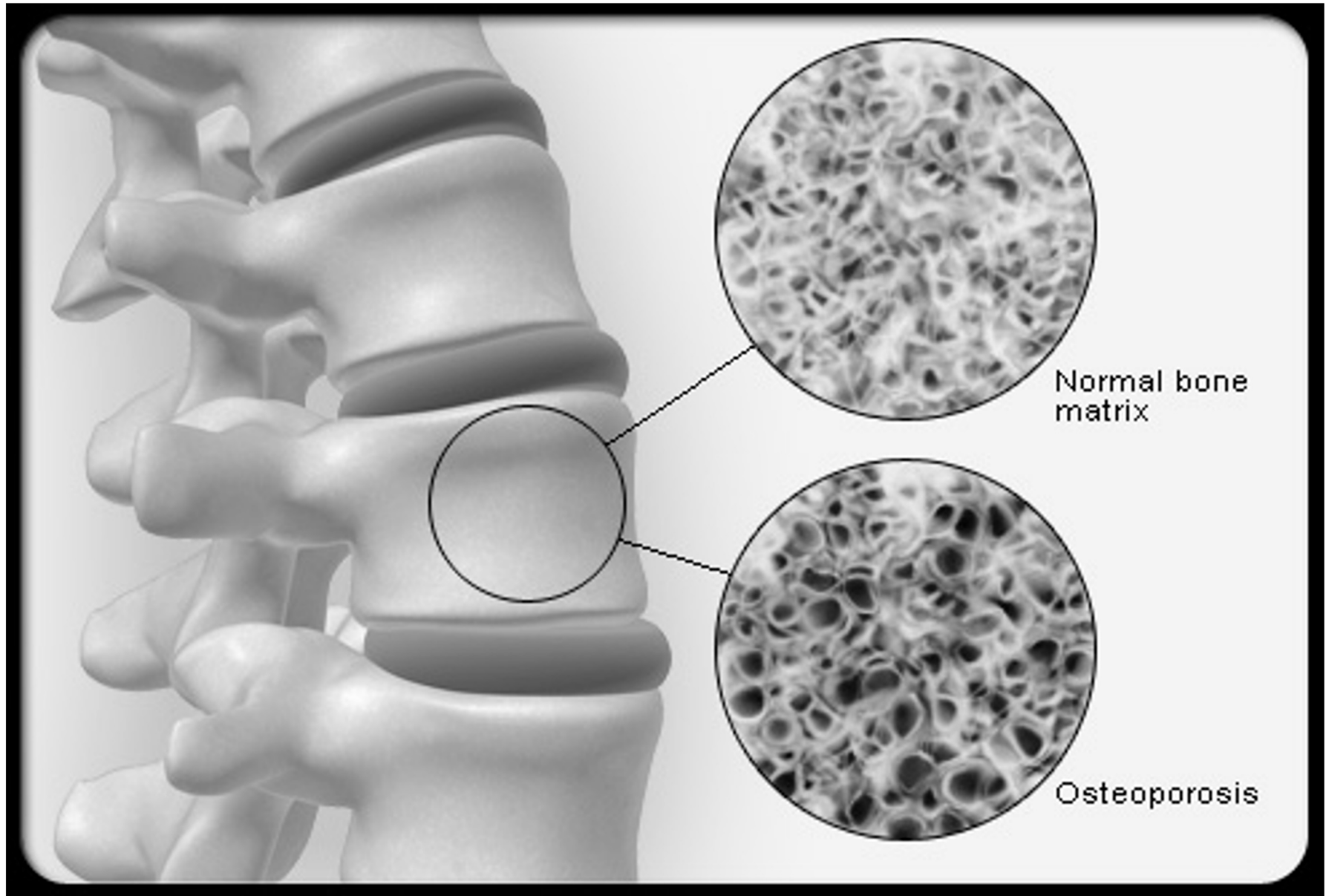
Complications of Osteomyelitis

- Septicemia
- Acute bacterial arthritis
- Pathologic fractures
- Squamous cell carcinoma
- Amyloidosis
- Chronic osteomyelitis*
- Tuberculous osteomyelitis: long bones, vertebrae (Pott's disease)



Osteoporosis

- Reduction of bone mass per unit of bone volume
- Metabolic bone disease
- Bone displays normal ratio of mineral to matrix
- Primary and secondary



Normal bone
matrix

Osteoporosis

Primary Osteoporosis

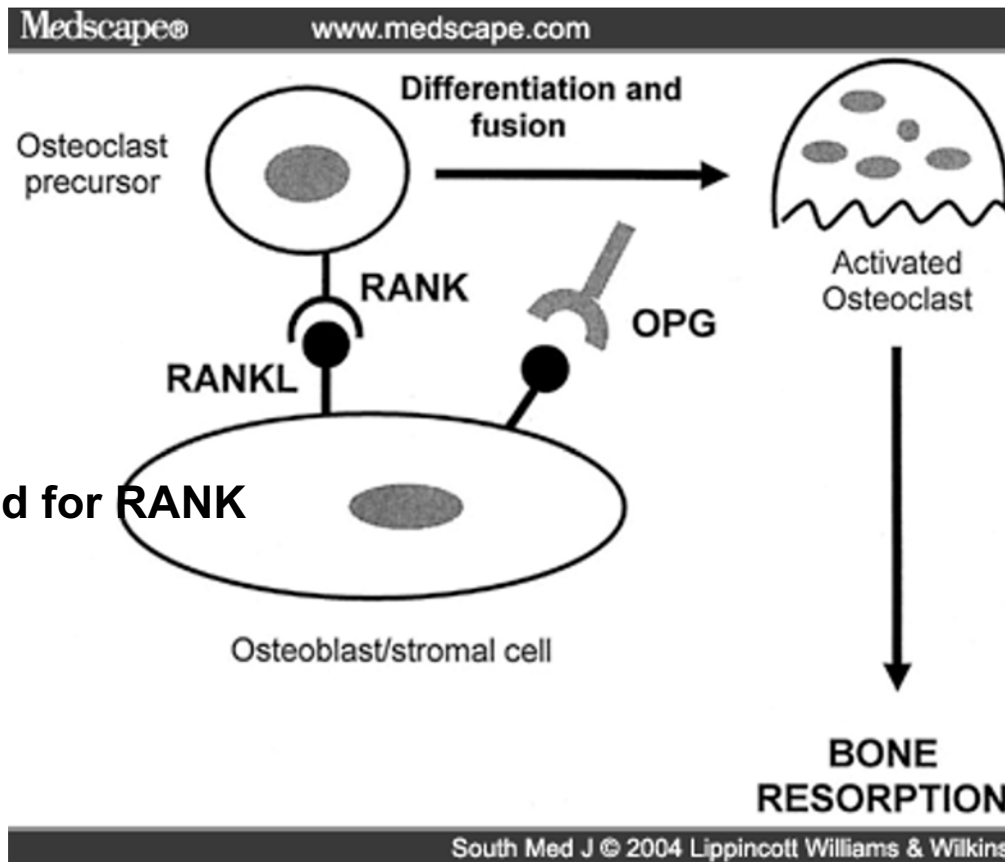
- Most common
 - Decreased bone mass with a normal ratio of mineral to matrix
- Etiology
 - is a lack of certain hormones, particularly estrogen in women and androgen in men
- Postmenopausal women
- Elderly persons (senile)
 - Genetic: peak bone mass
 - Estrogens: decline
 - Aging
 - Calcium intake (800mg/day)
 - Exercise
 - Environmental factors: smoking leads to estrogen ↓

Primary Osteoporosis

- Osteopenia
- Decrease thickness of cortex
- Reduction in the number and size of trabeculae
- Fractures can be the first sign
- Compression fractures of vertebrae

Some terms

- RANK: receptor activator for nuclear factor κ B
 - Macrophages, stromal cells
- RANKL: ligand for RANK
 - under the influence of factors such as PTH and 1,25-dihydroxyvitamin D
- RANKL and Macrophage-Colony Stimulating Factor convert macrophages to osteoclasts
- RANK-RANKL is regulated by Osteoprotegerin (OPG)
- OPG-RANKL curtails osteoclast formation and bone-resorption activity



**RANK: receptor
activator for nuclear
factor κ B**

RANKL: ligand for RANK

A schematic overview of the RANKL/RANK/OPG system. RANKL mediates a signal for osteoclast formation through RANK expressed on osteoclast progenitors. OPG counteracts this effect by competing for and neutralizing RANKL. (Adapted with permission from Yasuda H, Shima N, Nakagawa N, et al. Osteoclast differentiation factor is a ligand for osteoprotegerin/ osteoclastogenesis-inhibitory factor and is identical to TRANCE/RANKL. Proc Natl Acad Sci U S A 1998;95:3597-3602. Copyright ©1998 National Academy of Sciences, U.S.A.)

Menopause

- Decreased serum estrogen
- Increased IL-1, IL-6 and TNF-levels
- Increased expression of RANK and RANKL
- Increased osteoclastic activity

Aging

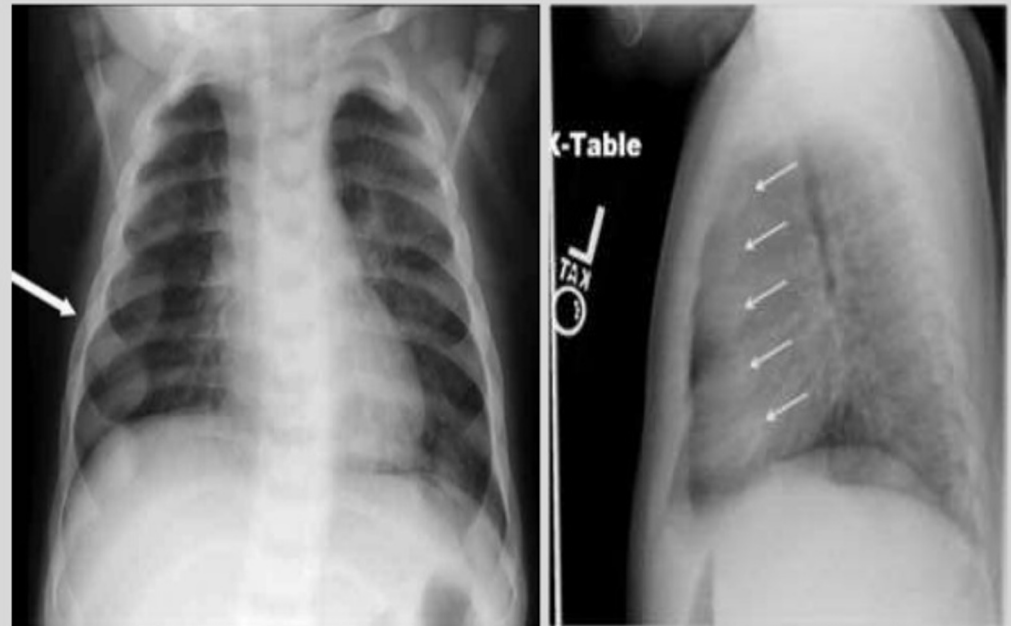
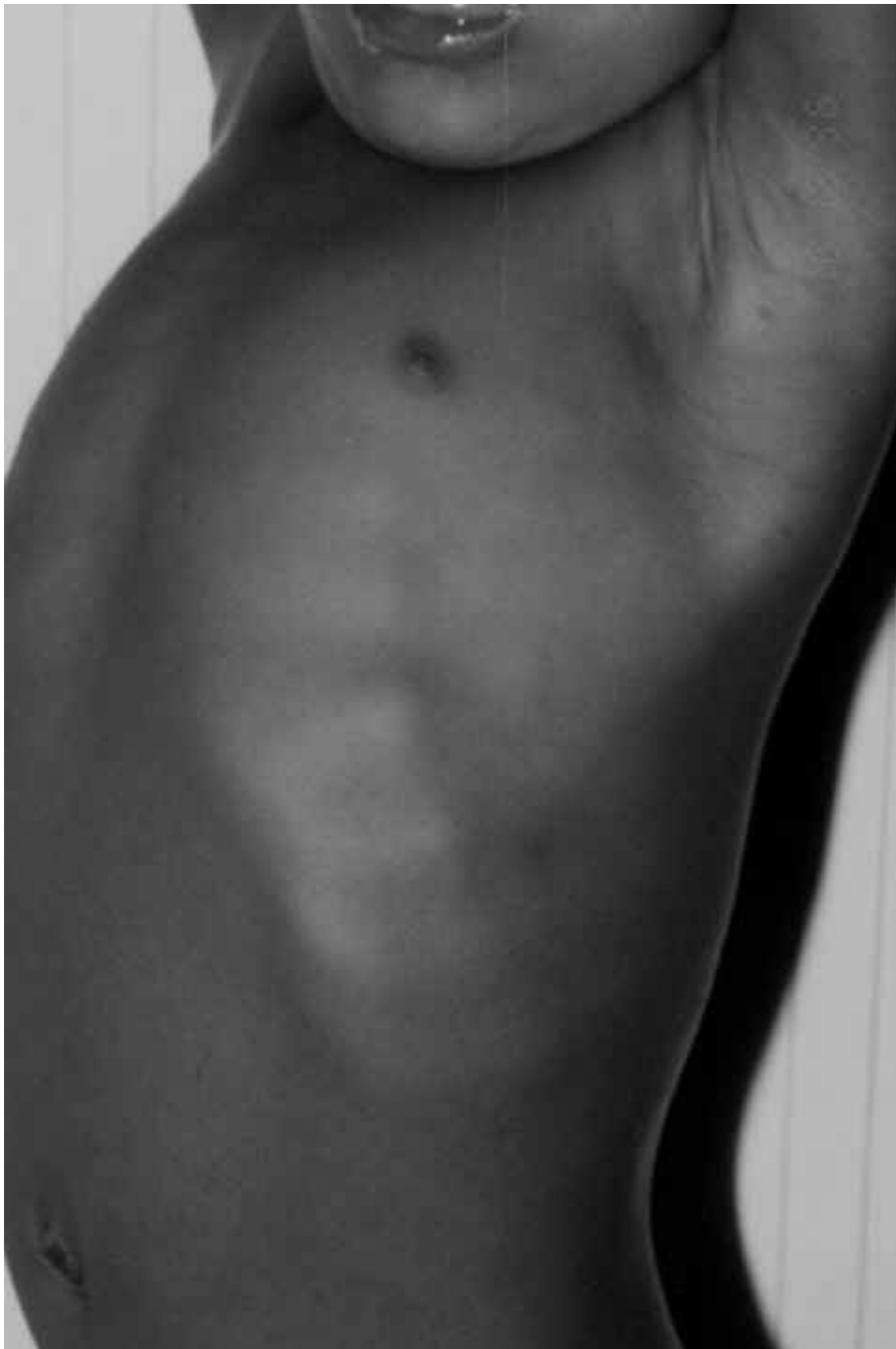- Decreased replicative activity of osteoprogenitor cells
- Decreased synthetic activity of osteoblasts
- Decreased biologic activity of matrix-bound growth factors
- Reduced physical activity

Secondary Osteoporosis

- Corticosteroids
 - Inhibition of osteoblastic activity
 - Impairment of vit. D dependant intestinal calcium absorption (secondary hyperparathyroidism)
- Hematologic malignancies
- Malabsorption: GI and liver diseases
- Alcoholism
 - Inhibition of osteoblasts,
 - ↓ absorption of calcium

Osteomalacia and Rickets

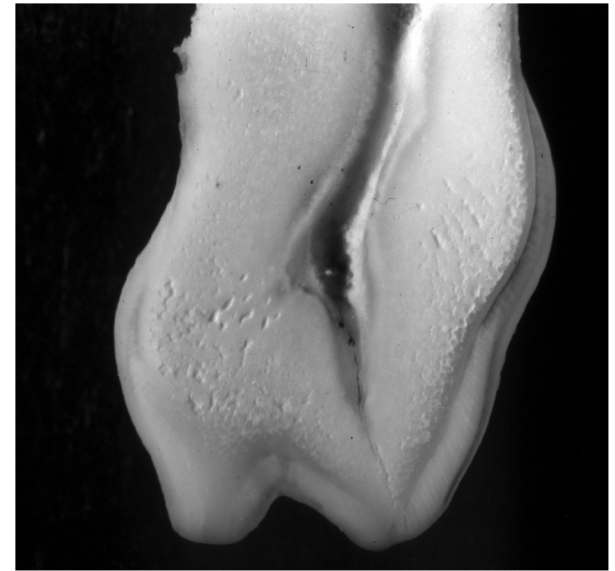
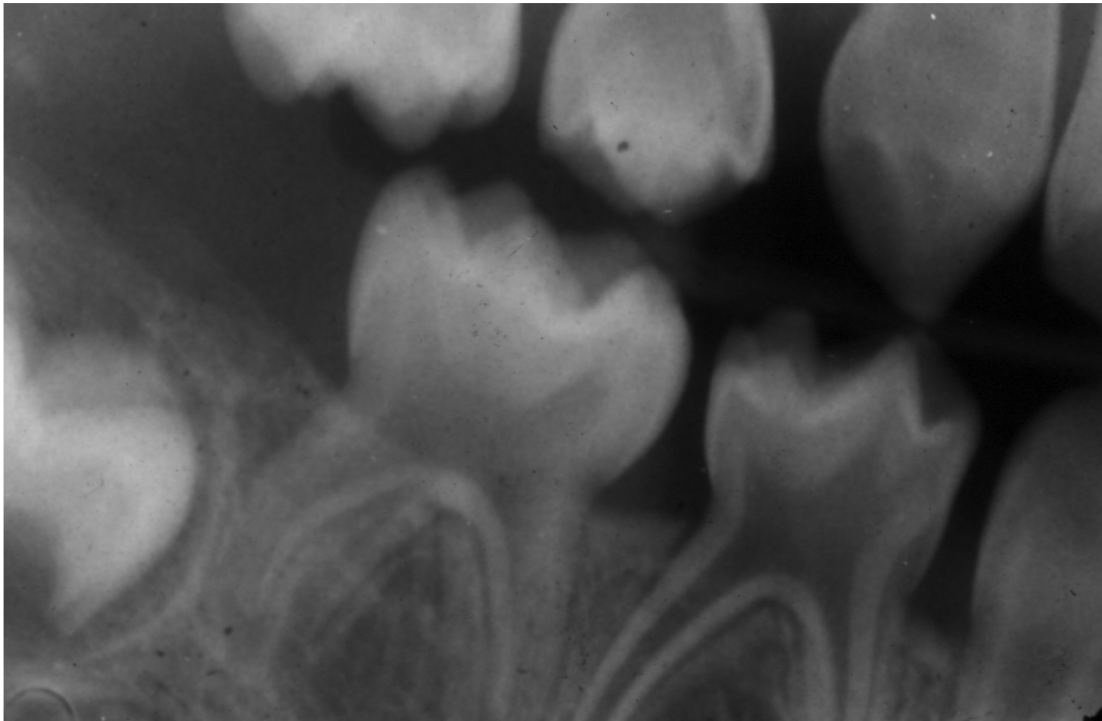
- Inadequate mineralization of newly formed bone matrix (osteomalacia)
- Rickets: children, epiphyseal plates open; also problem with cartilage
 - Beaded appearance of costochondral junctions
 - Pectus carinatum
 - Dental abnormalities
- Vitamin D deficiency and hereditary vitamin D dependent rickets
- Phosphate deficiency (resistant rickets; X-linked or AR)
 - Hypophosphatemia, defective intestinal absorption of calcium, and rickets or osteomalacia unresponsive to vitamin D
- Defects in mineralization process



Rachitic Rosary-enlarged costochondral junctions of the ribs in rickets resembling a string of rosary beads.



Vitamin D-resistant Rickets



Osteomalacia and Rickets

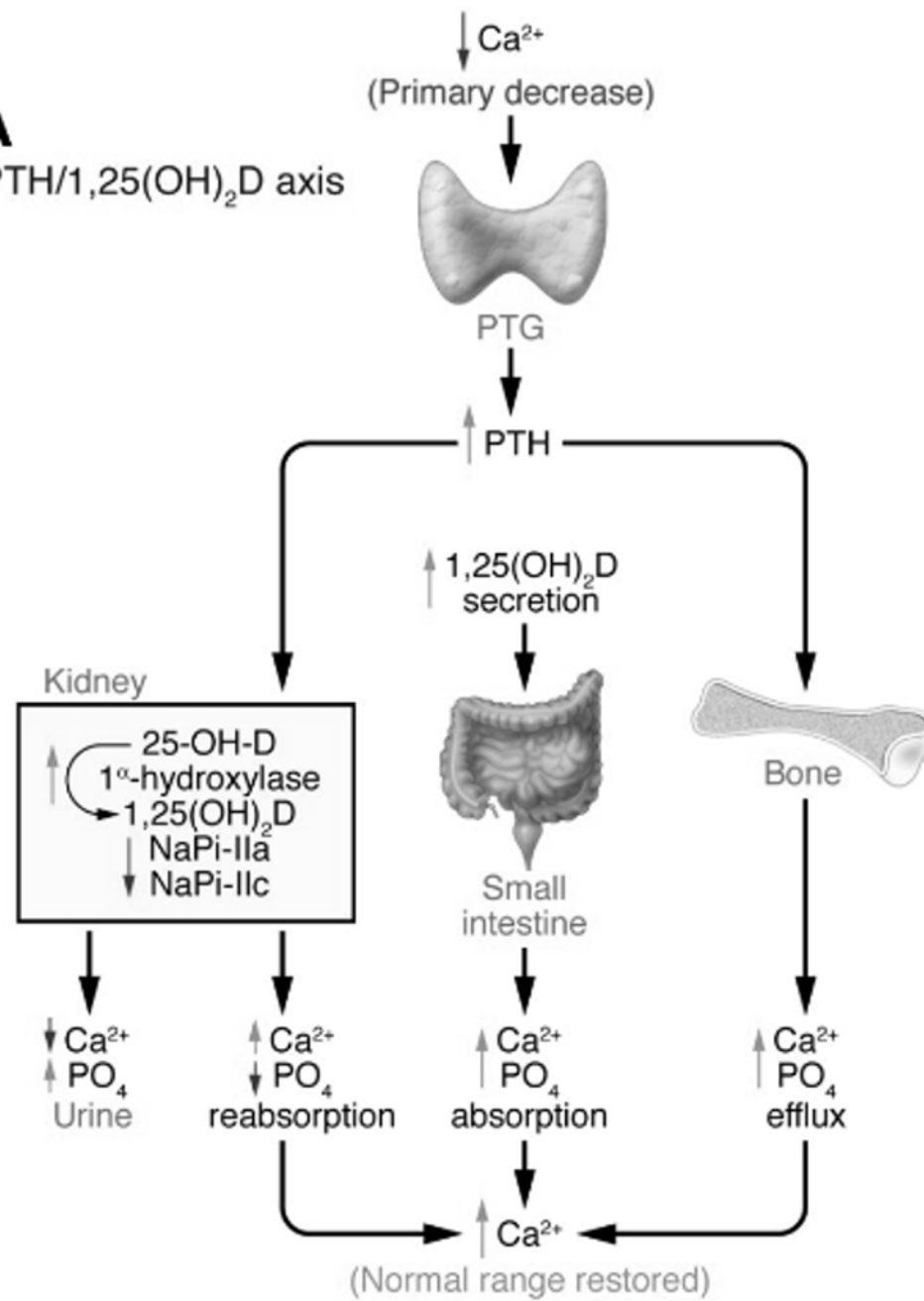
- Osteopenia
 - Decreased ratio of bone mineral to matrix
- Exaggeration of osteoid seams
- Poorly localized pain
- Femoral neck, pubic ramus, spine, ribs

Hyperparathyroidism

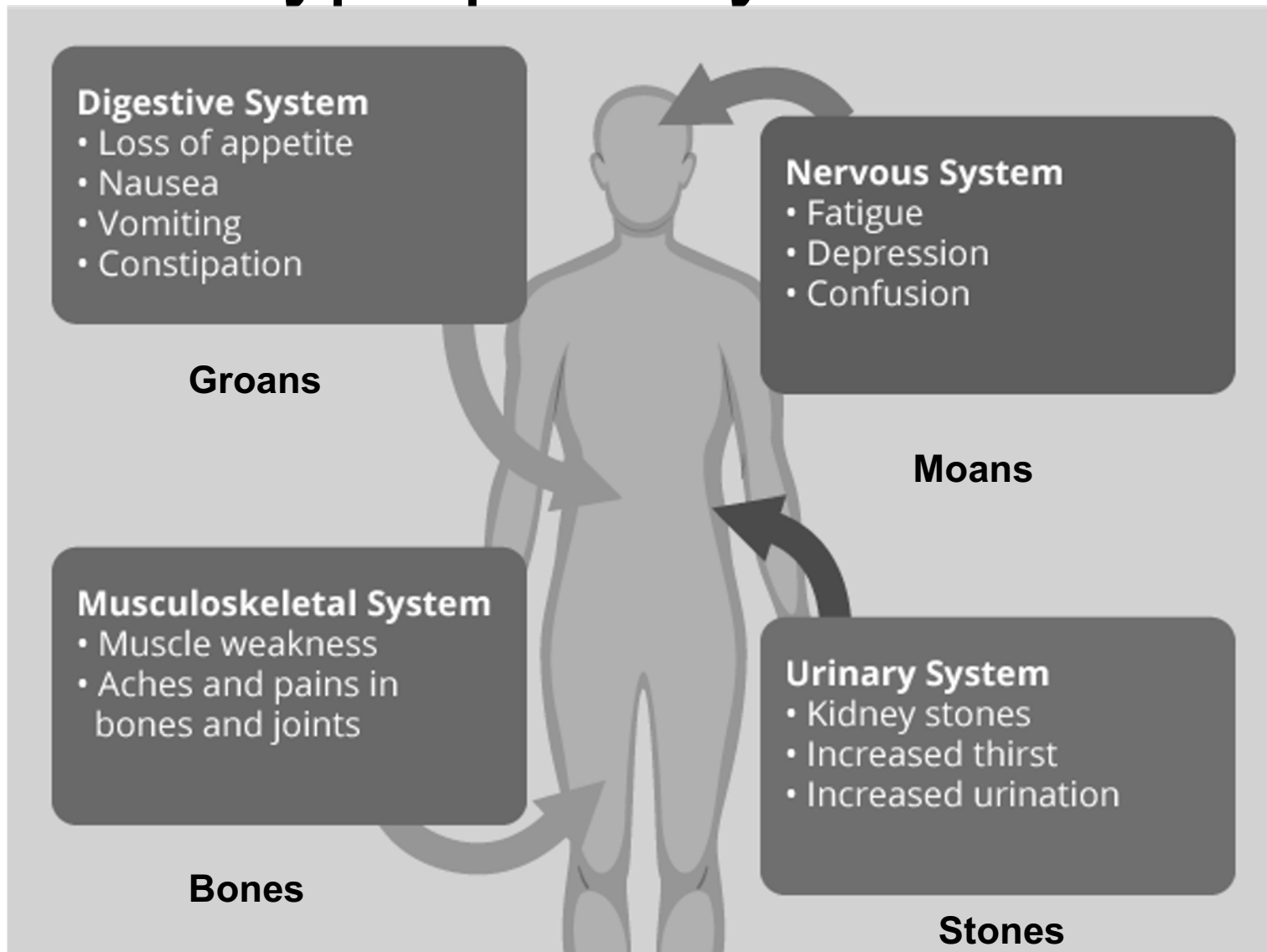
- Parathyroid adenoma, hyperplasia, rare malignancy
- Parathyroid hormone
 - Promotes excretion of phosphate in the urine and stimulates osteoclastic activity resulting in hypercalcemia
 - Stimulates tubular reabsorption of calcium and excretion of phosphate
 - Stimulates intestinal calcium absorption

A

PTH/1,25(OH)₂D axis

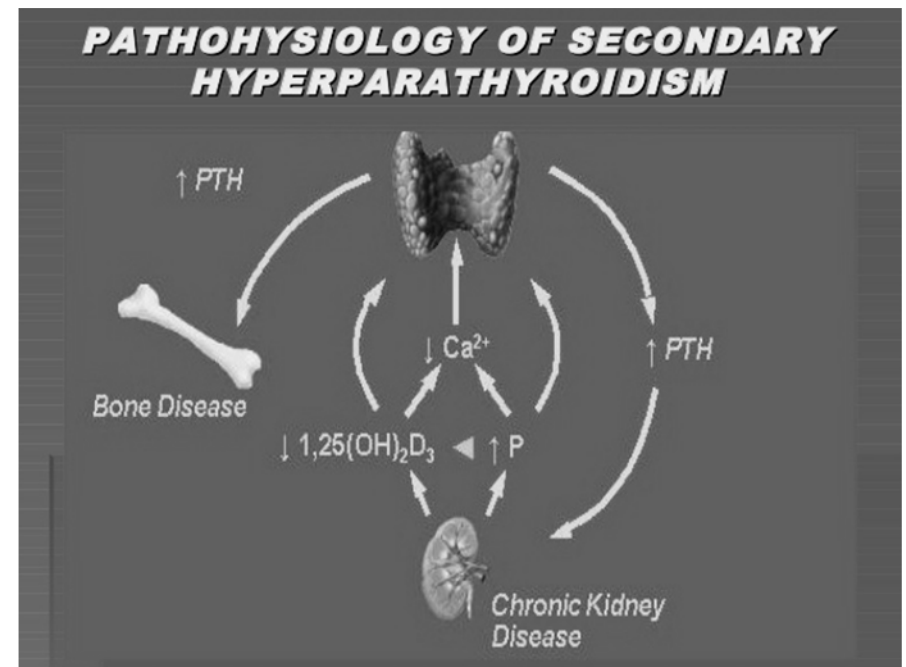


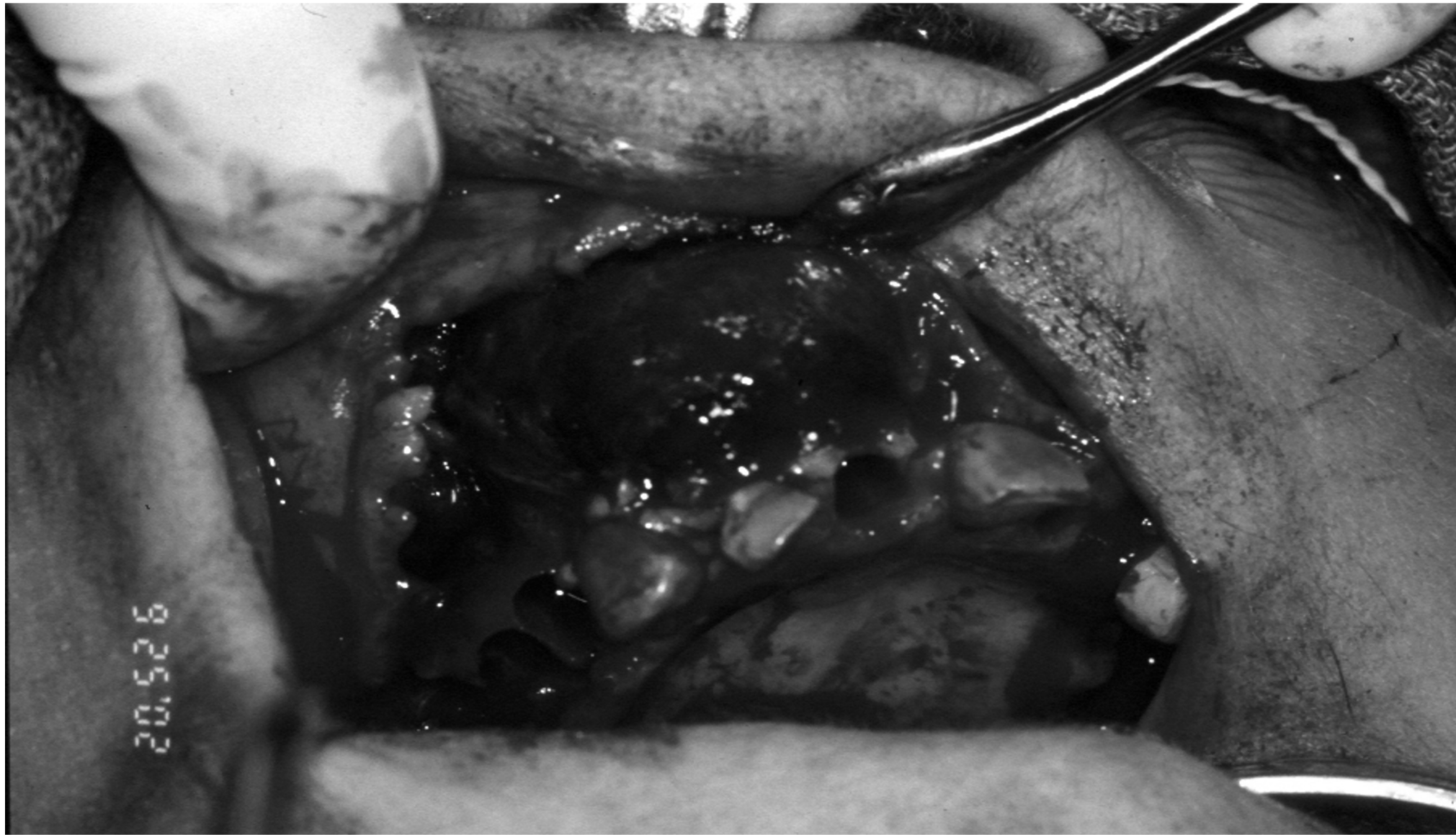
Hyperparathyroidism

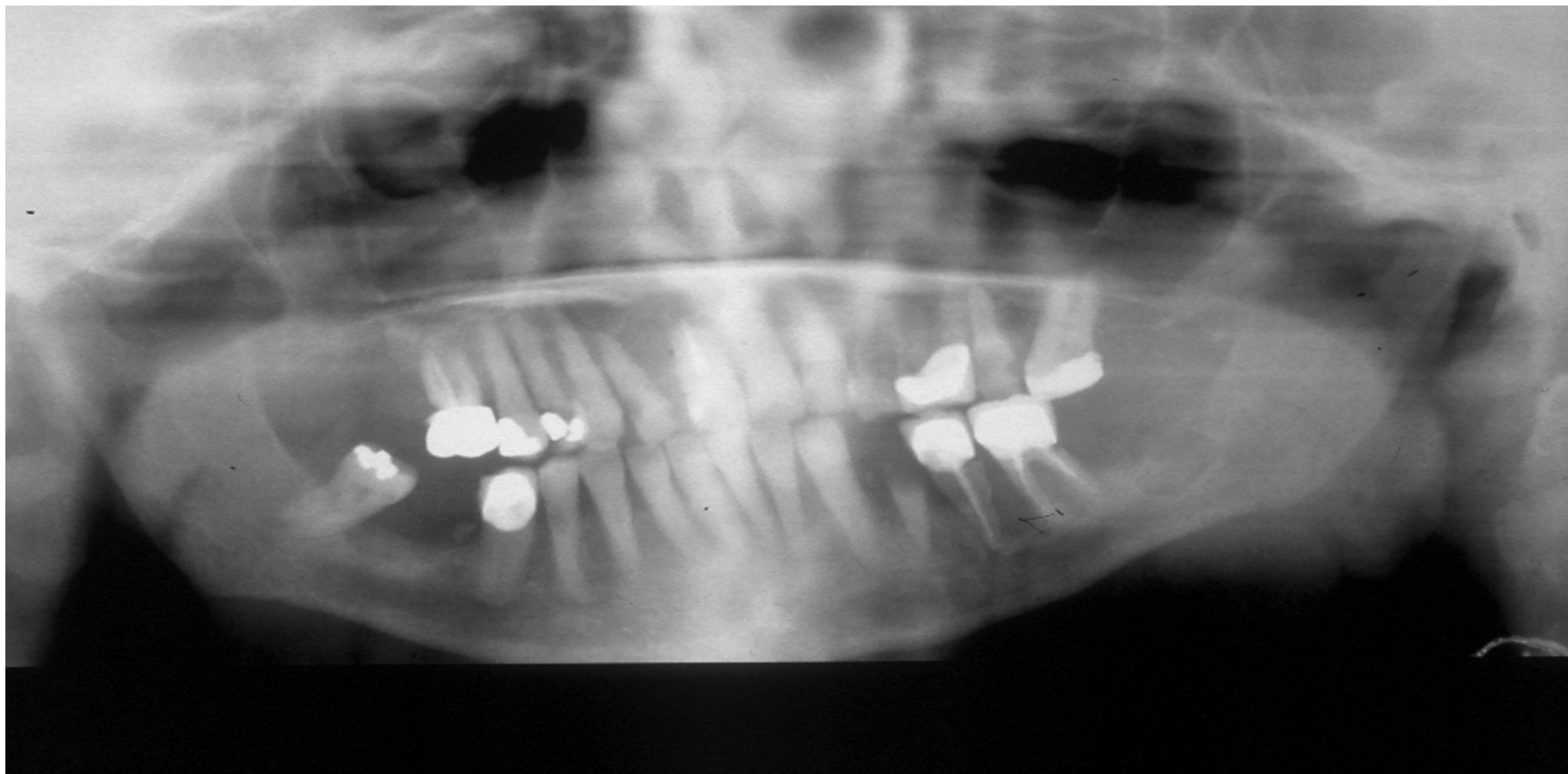


Secondary hyperparathyroidism

- Renal osteodystrophy
 - Failure to maintain proper levels of calcium and phosphorus in the blood
 - Dialysis
 - Decreased filtration of phosphate
 - Hyperphosphatemia
 - Effect on active vitamin D
 - Decreased Ca absorption in GI
 - Hypocalcemia
 - Secondary hyperparathyroidism







LightSpeed QX[®] CT02_OC0
Ex 12040
S₁ 2
Im 5
OM 122.5
DFOV 18.0cm
STANDARD

AS

HENRY FORD DETROIT, MI
WEATHINGTON

S
H
I

R
9
0

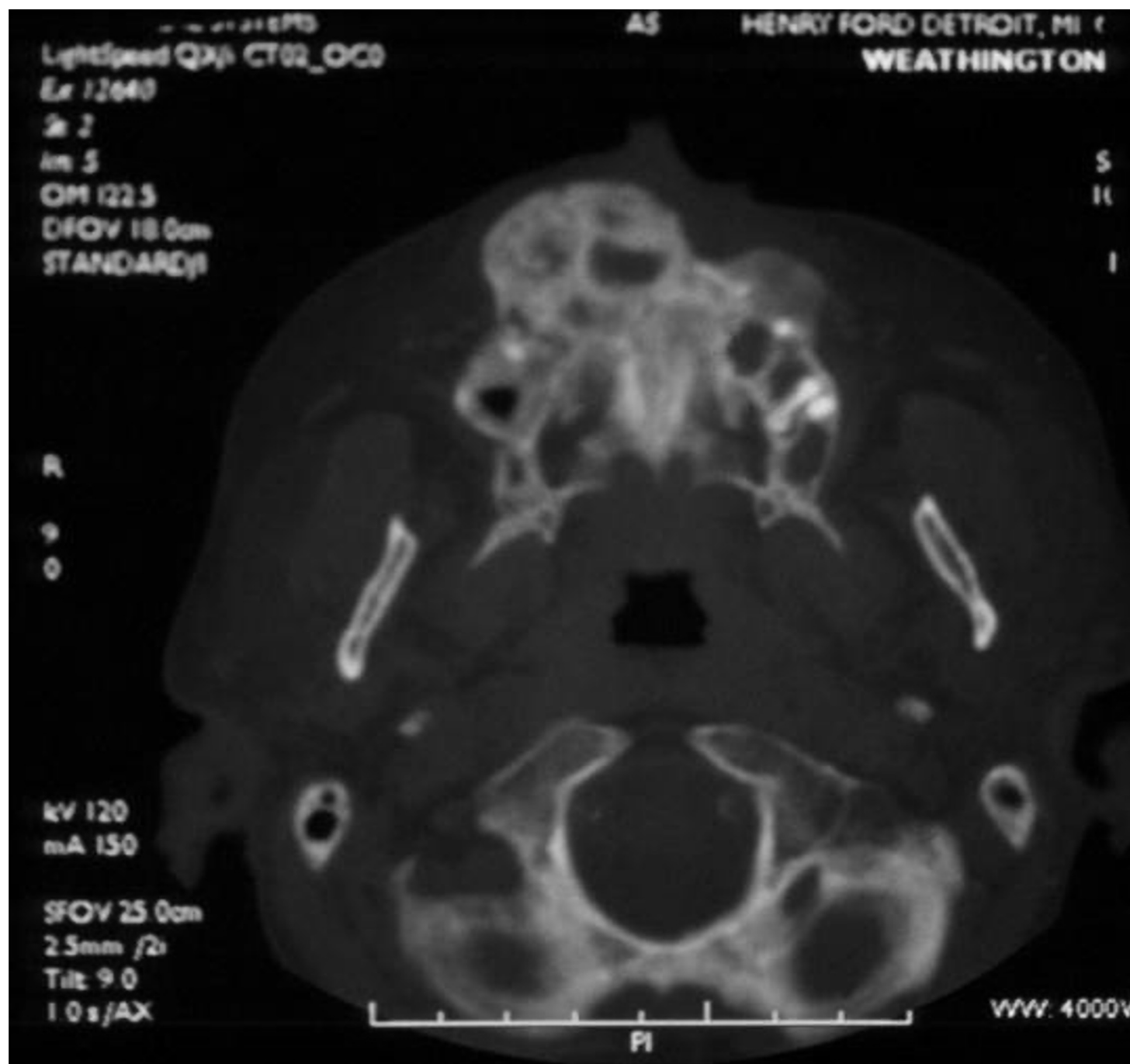
kV 120
mA 150

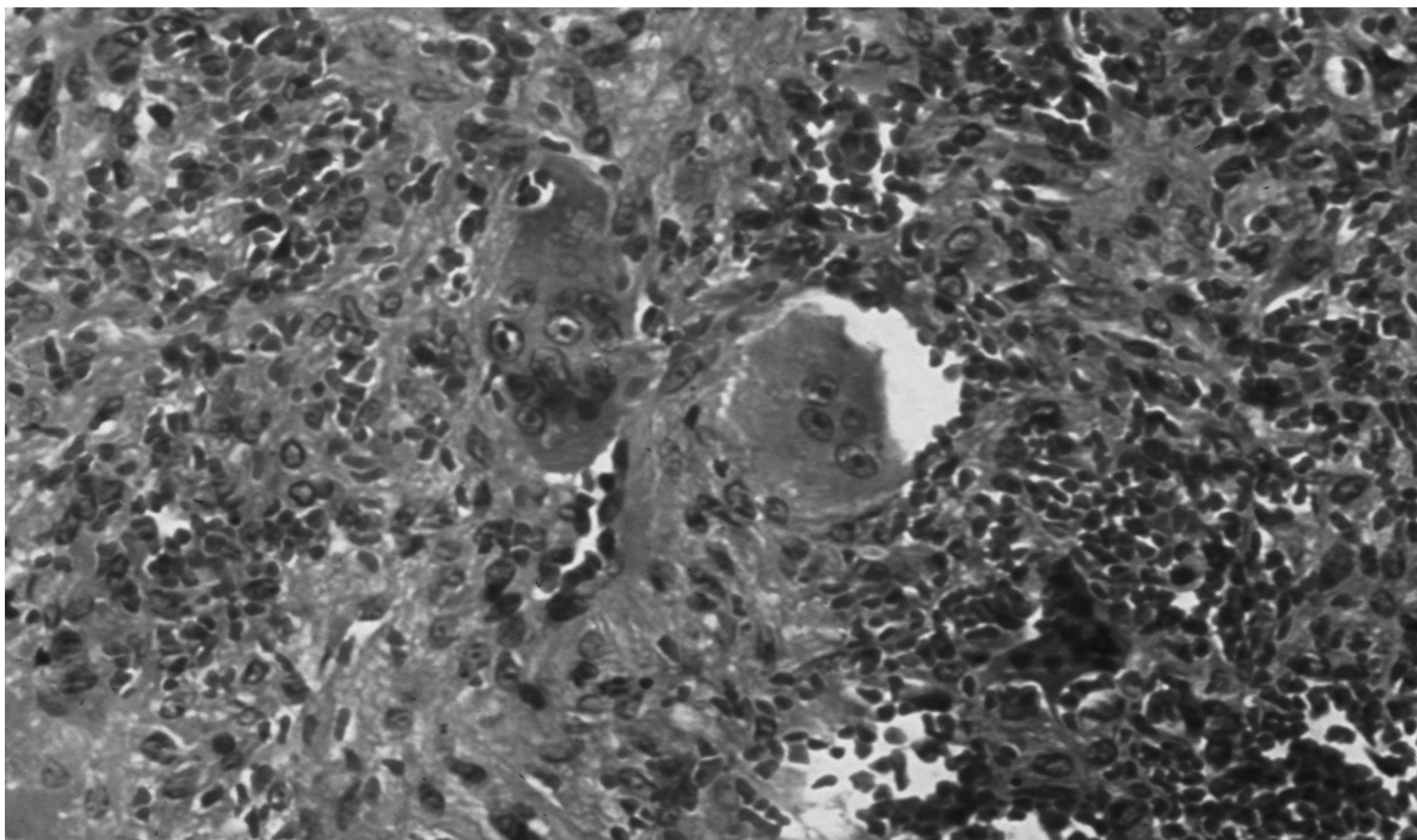
SFOV 25.0cm
2.5mm /2s
Tilt 9.0
1.0 s/AX



PI

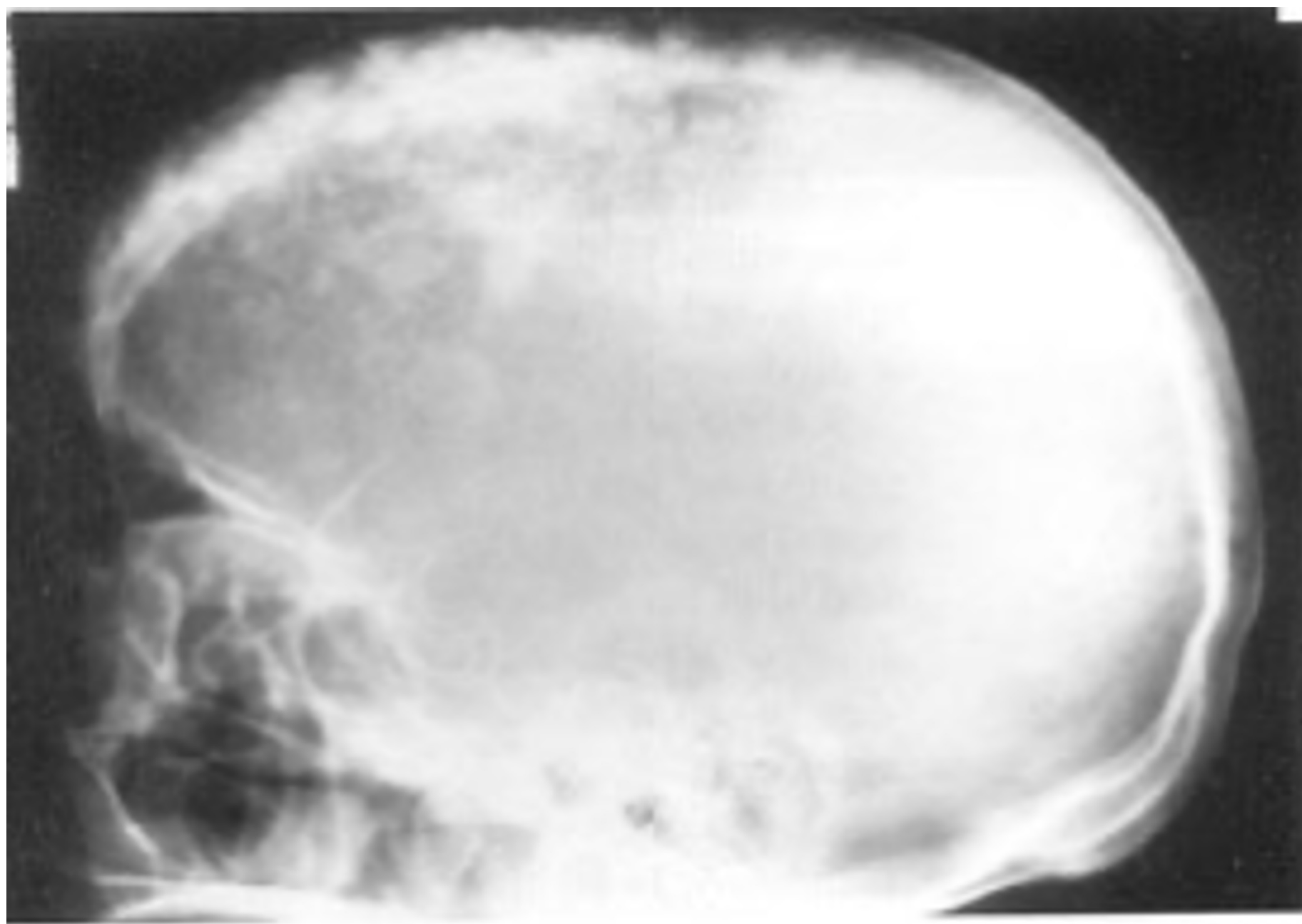
WWW: 4000V

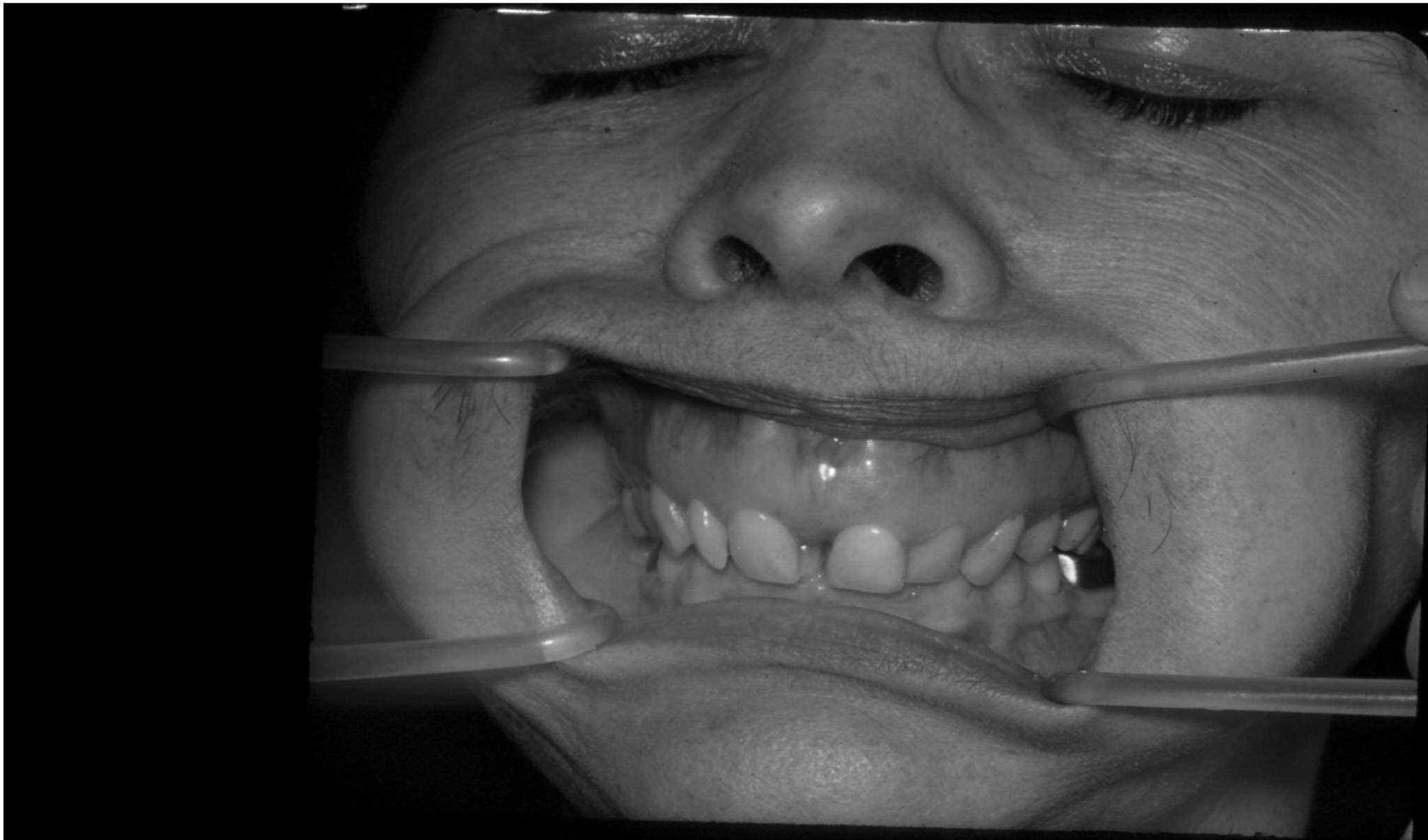

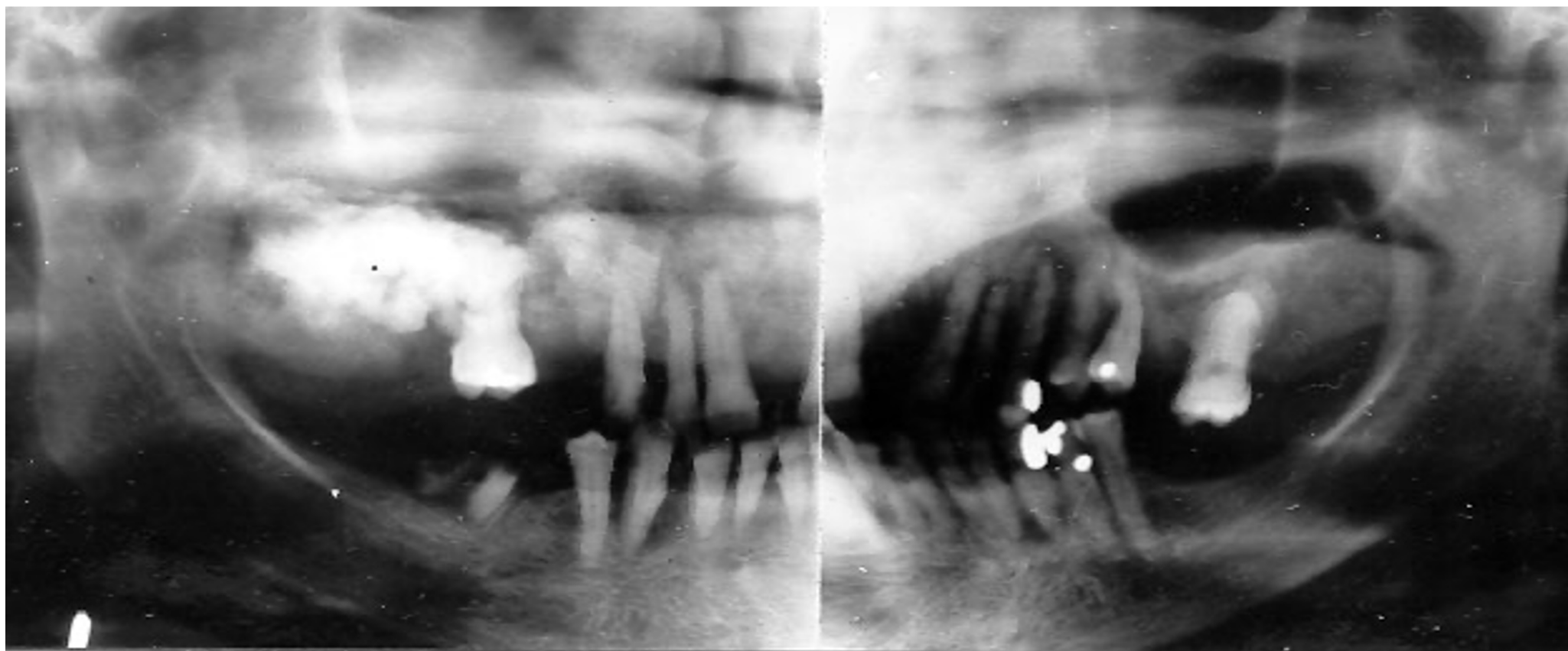


Paget Disease of Bone

- Disorder of bone remodeling
 - SQSTM1 and RANK
- Three phases
 - Osteoclastic (hot)
 - Mixed osteoblastic/osteoclastic
 - Burnt-out stage (cold)
- Skull involvement
 - Cotton wool appearance
 - Hypercementosis of jaws
- Tests
 - Alkaline phosphatase
 - Urine hydroxyproline levels
 - Urine pyridinoline

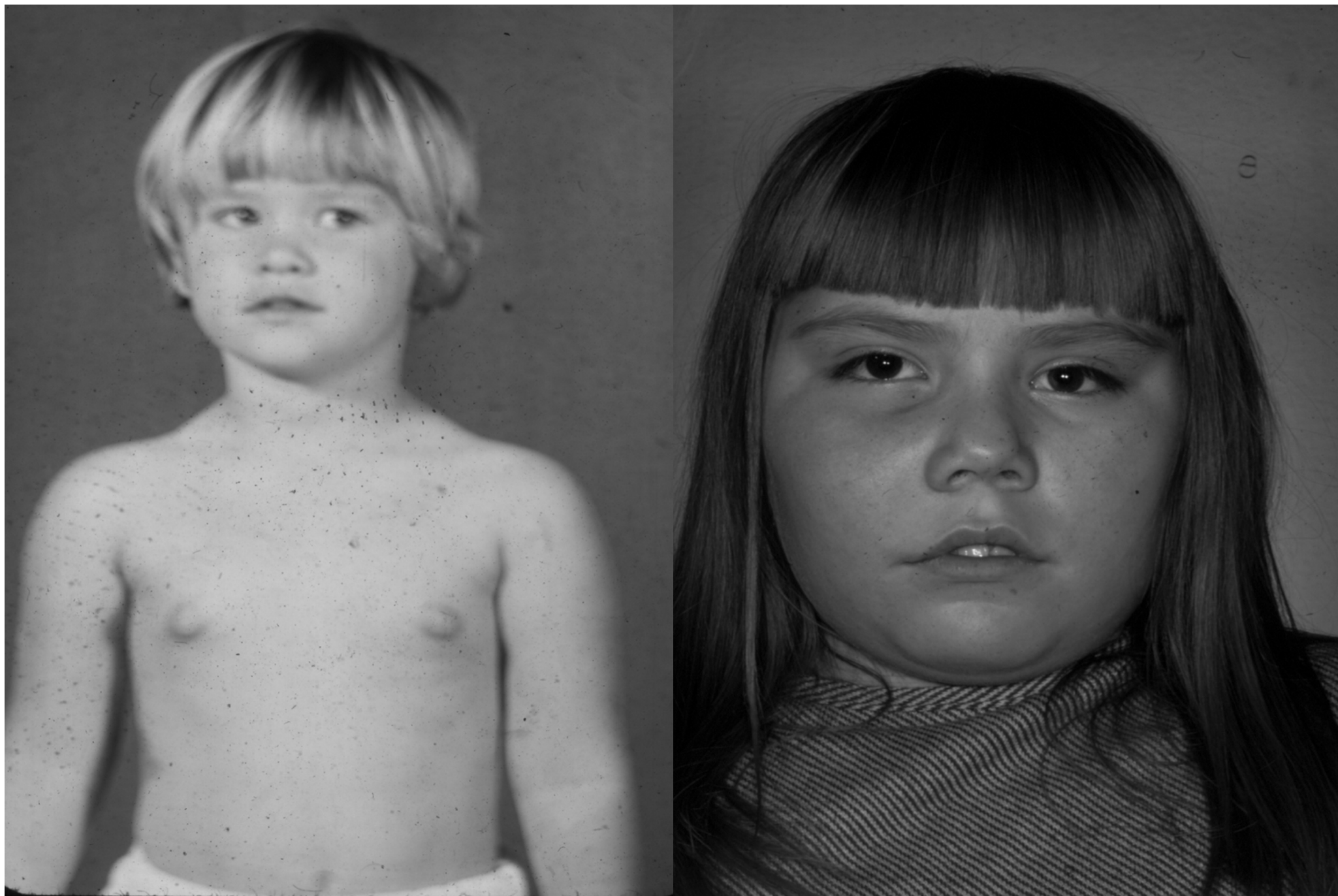


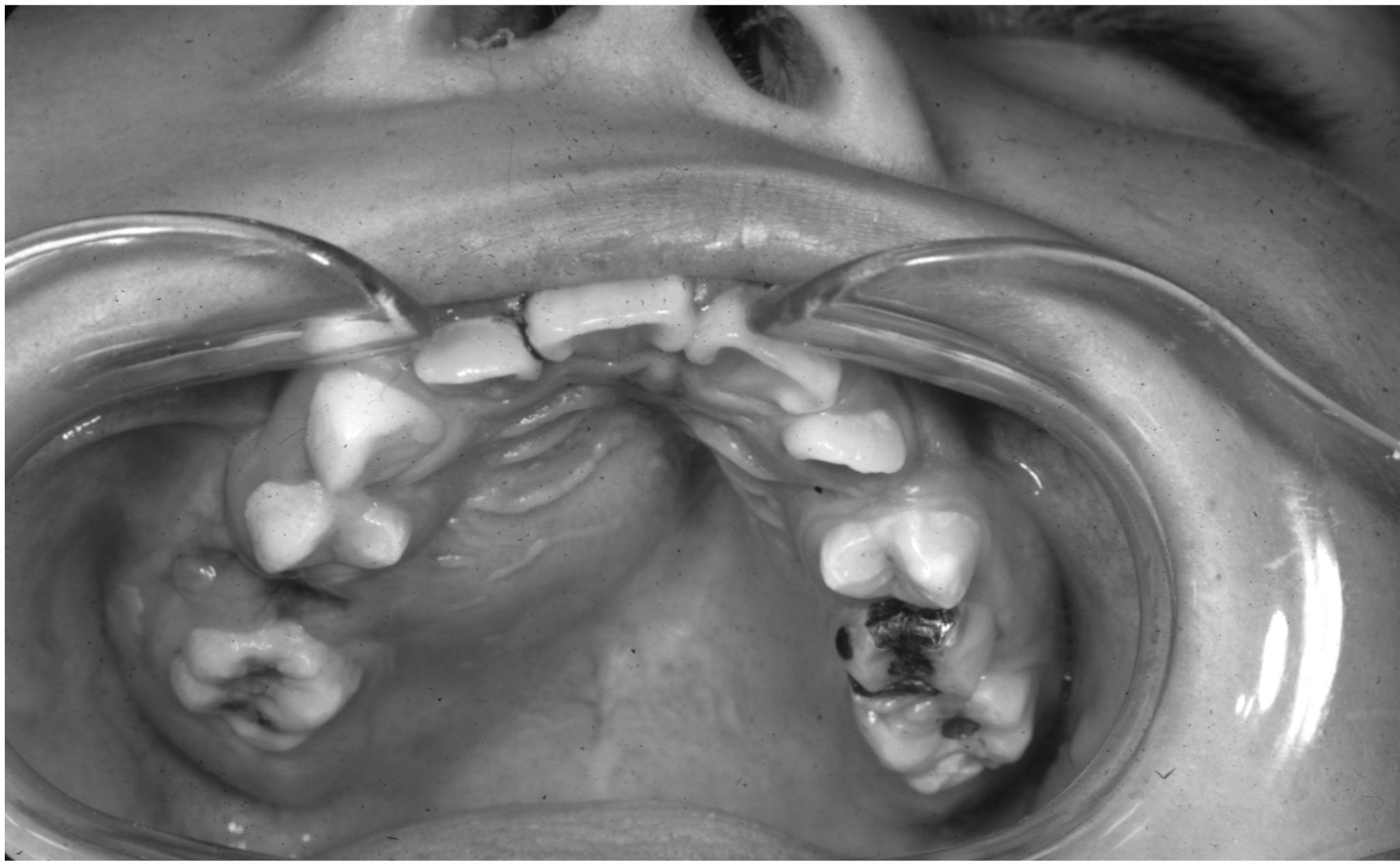


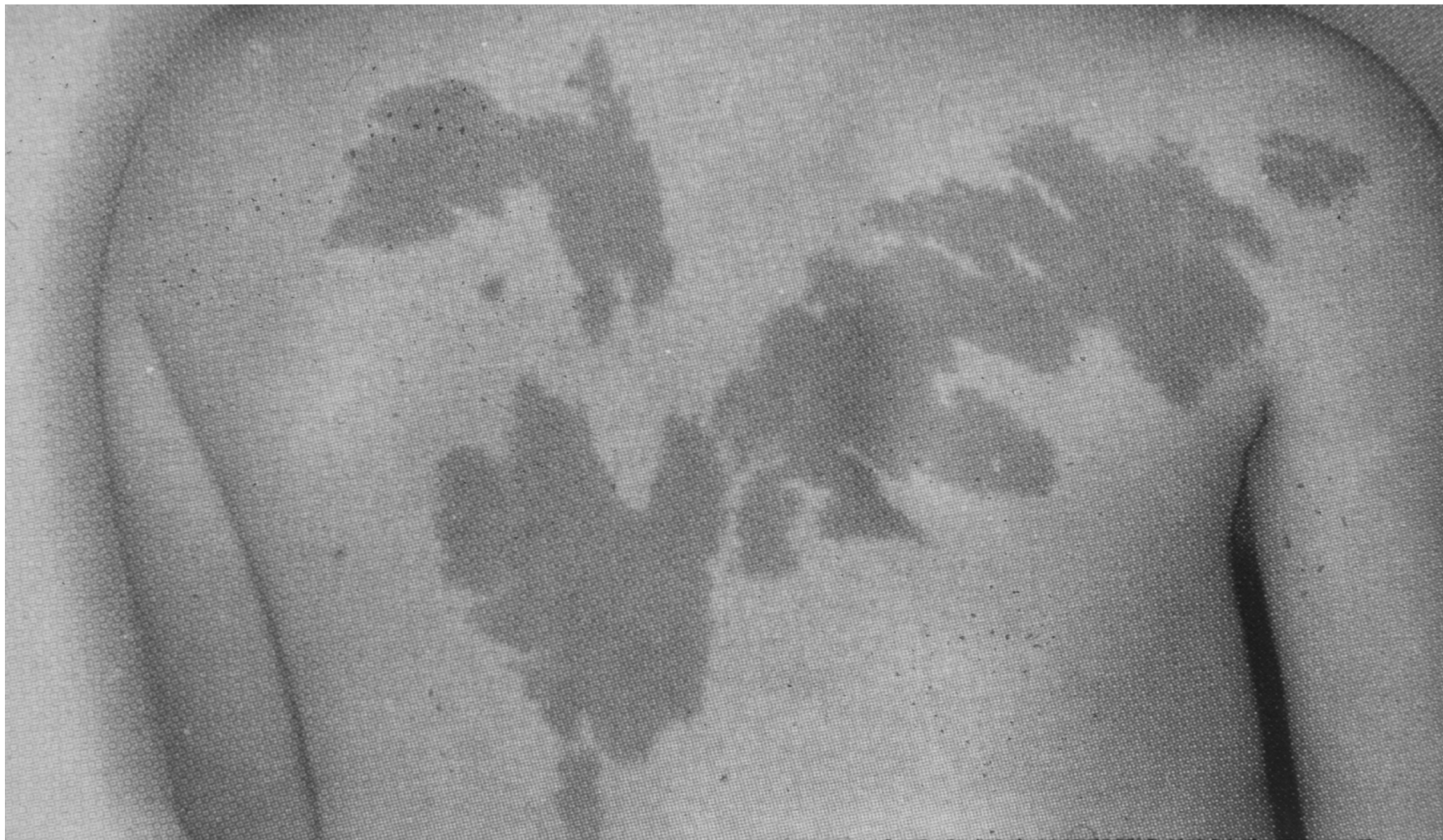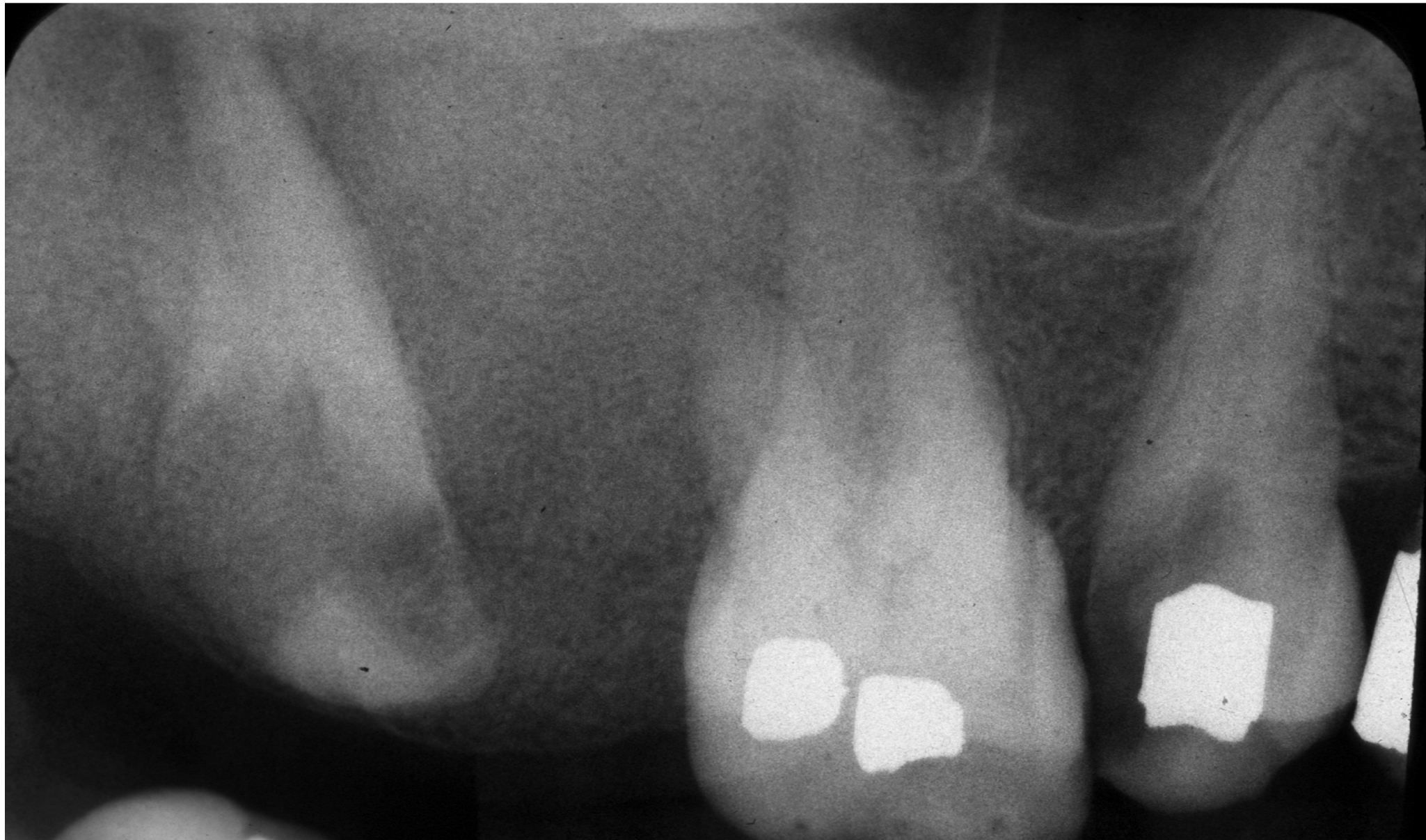Fibrous Dysplasia

- $G_s\alpha$
- McCune Albright syndrome
- Jaffe syndrome
- Monostotic
- Ground glass radiographic appearance









COLLINS, RICHARD 28

S 5 2.85

P +6

A 0

H 139

F 0

HF/S

120KV

150MA

C

L

CX

W2000
+250

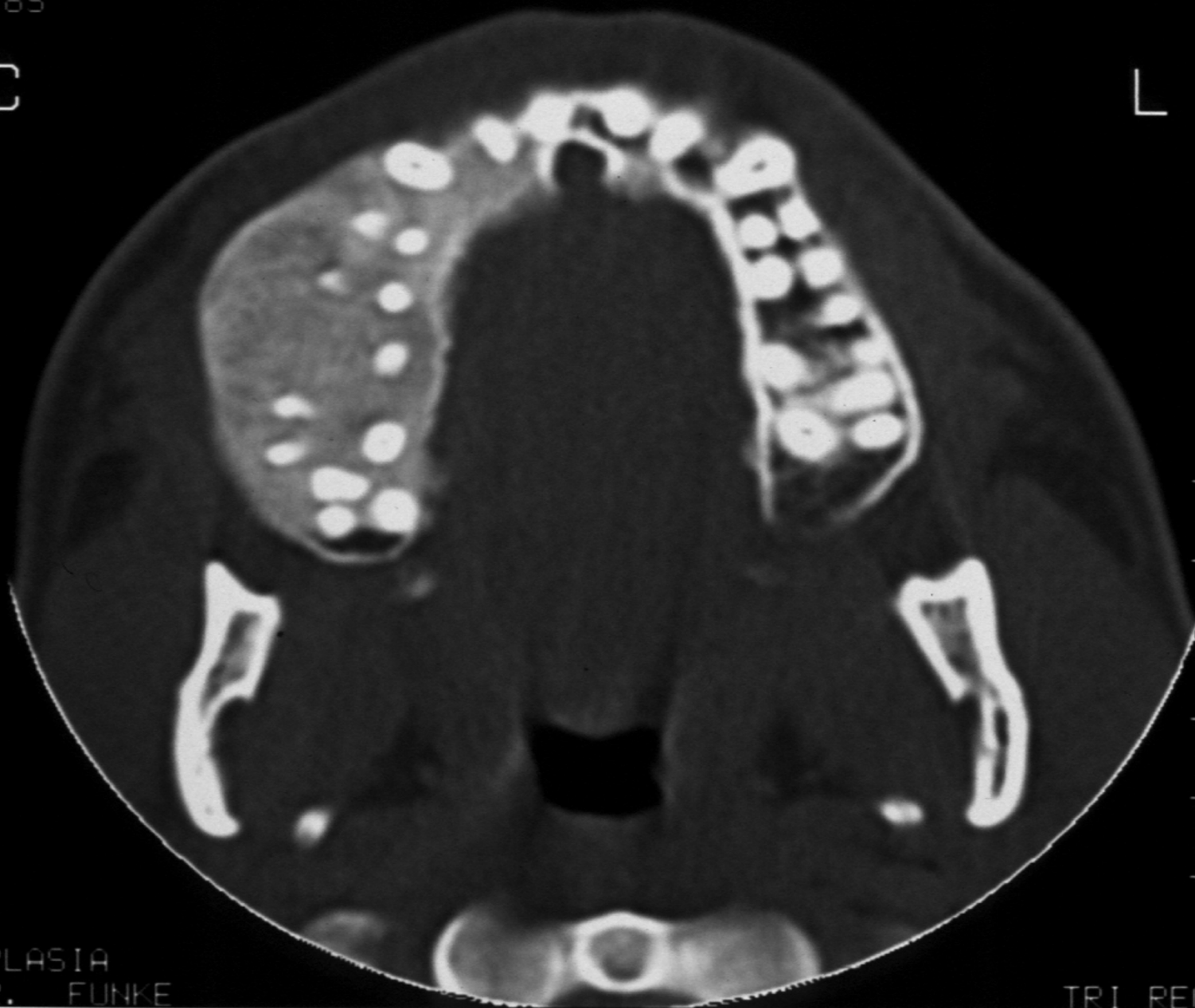512*512

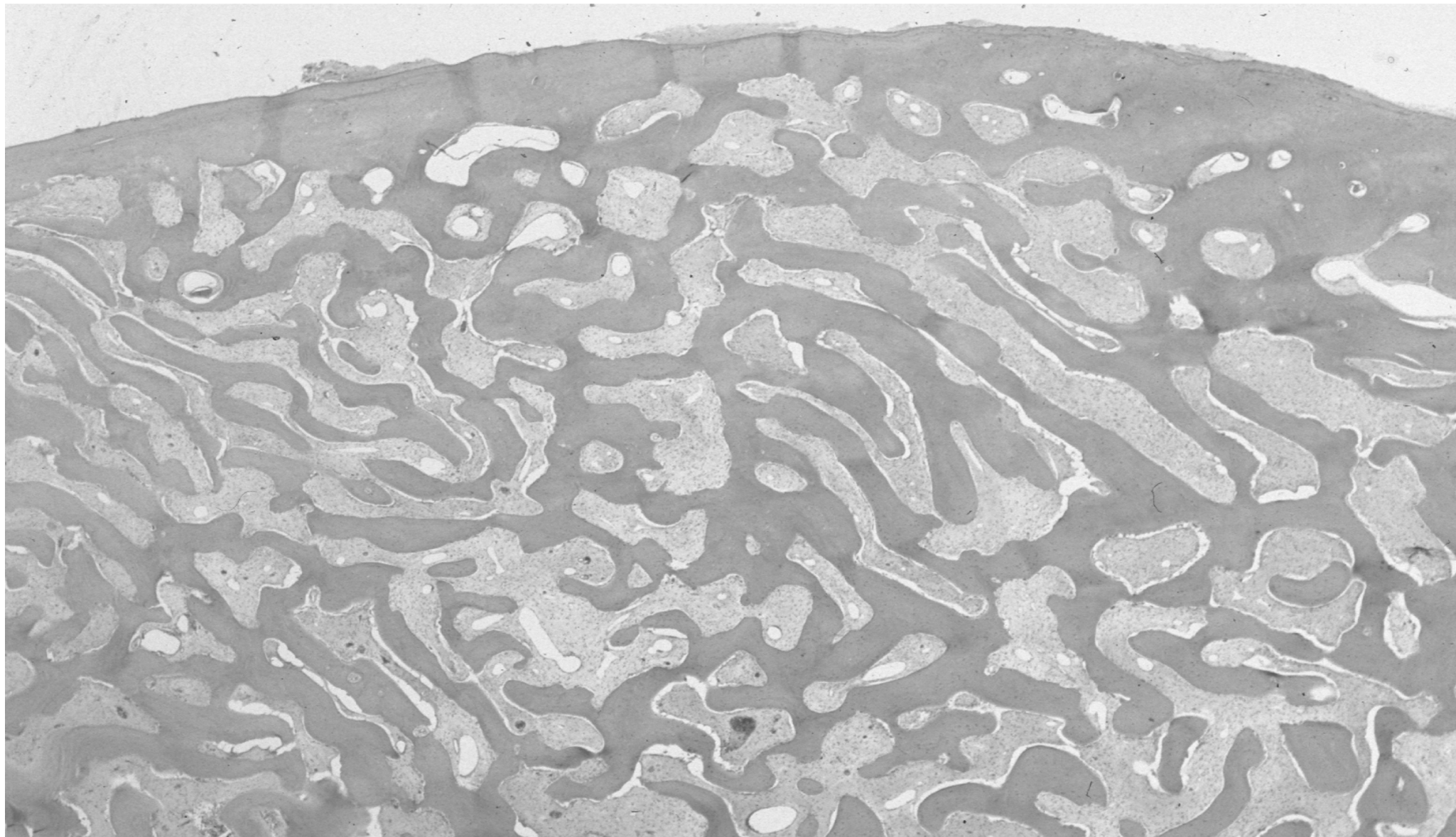
2M*1.8

SH*5

R/O NEOPLASIA
CDG/ DR. FUNKE

TRI REG MED CTR





Bone Tumors

- Bone Forming

- Benign

- Osteoma (face, skull; 40-50yrs; similar to normal bone)
 - Osteoid Osteoma: metaphysis femur, tibia; 10-20yrs; (woven bone)
 - Osteoblastoma: vertebral column; 10-20yrs; similar to osteoid osteoma

- Malignant

- Primary and secondary osteosarcoma (Paget' s disease)
 - 1°: Metaphysis of distal femur, proximal; 10-20 yrs; malignant cells produce osteoid
 - 2°: Femur, humerus, pelvis

Bone Tumors

- Cartilagenous

- Benign

- Osteochondroma: Metaphysis of long bones; 10-30 yrs; bone and cartilage as a cup
 - Chondroma: Small bones of hands and feet; 30-50 yrs; medullary cavity

- Malignant

- Chondrosarcoma: Femur, humerus, pelvis; 40-60 yrs; Within medullary cavity; malignant cells form cartilage (abnormal)

Bone Tumors

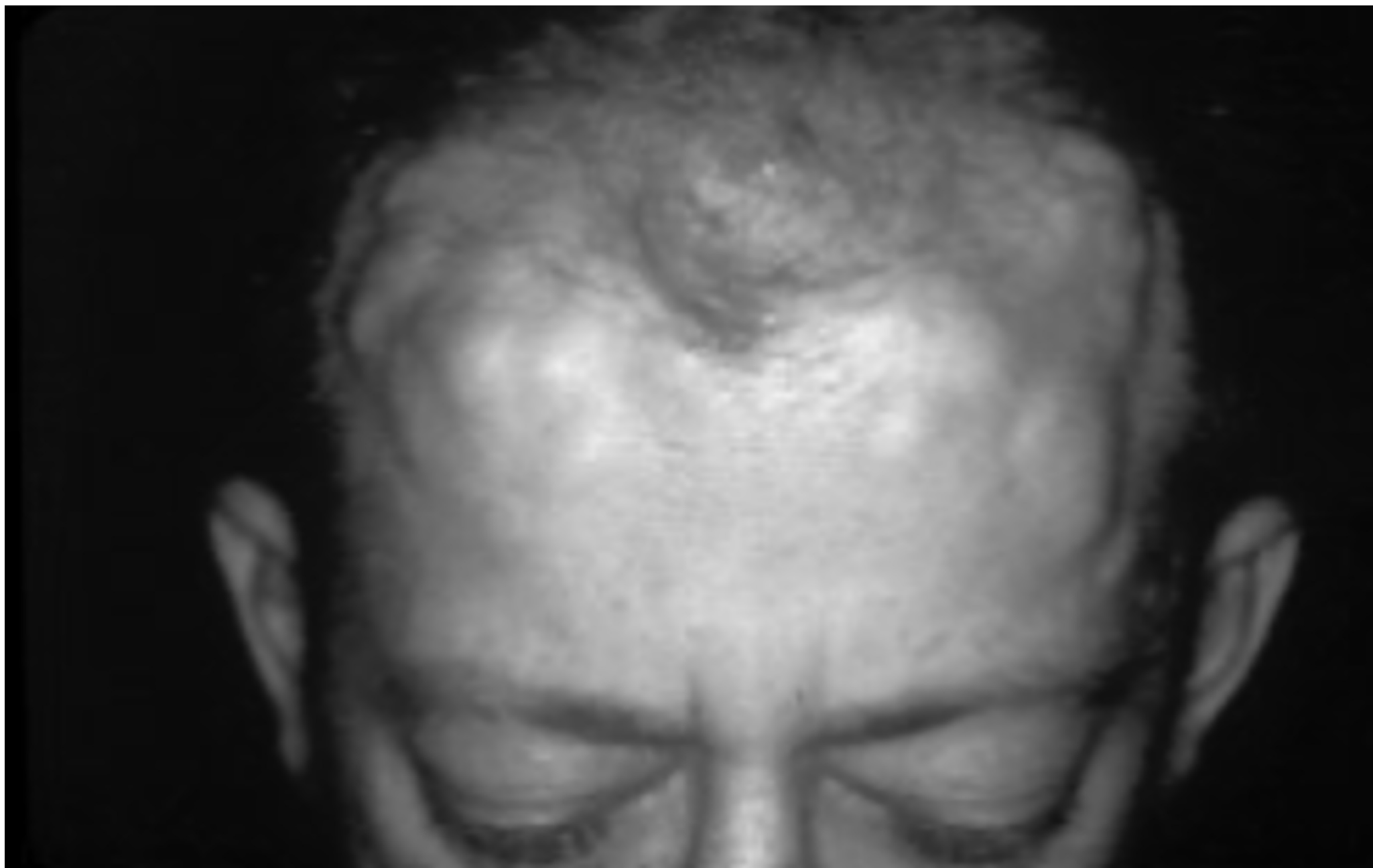
- Other

- Giant cell tumor of bone

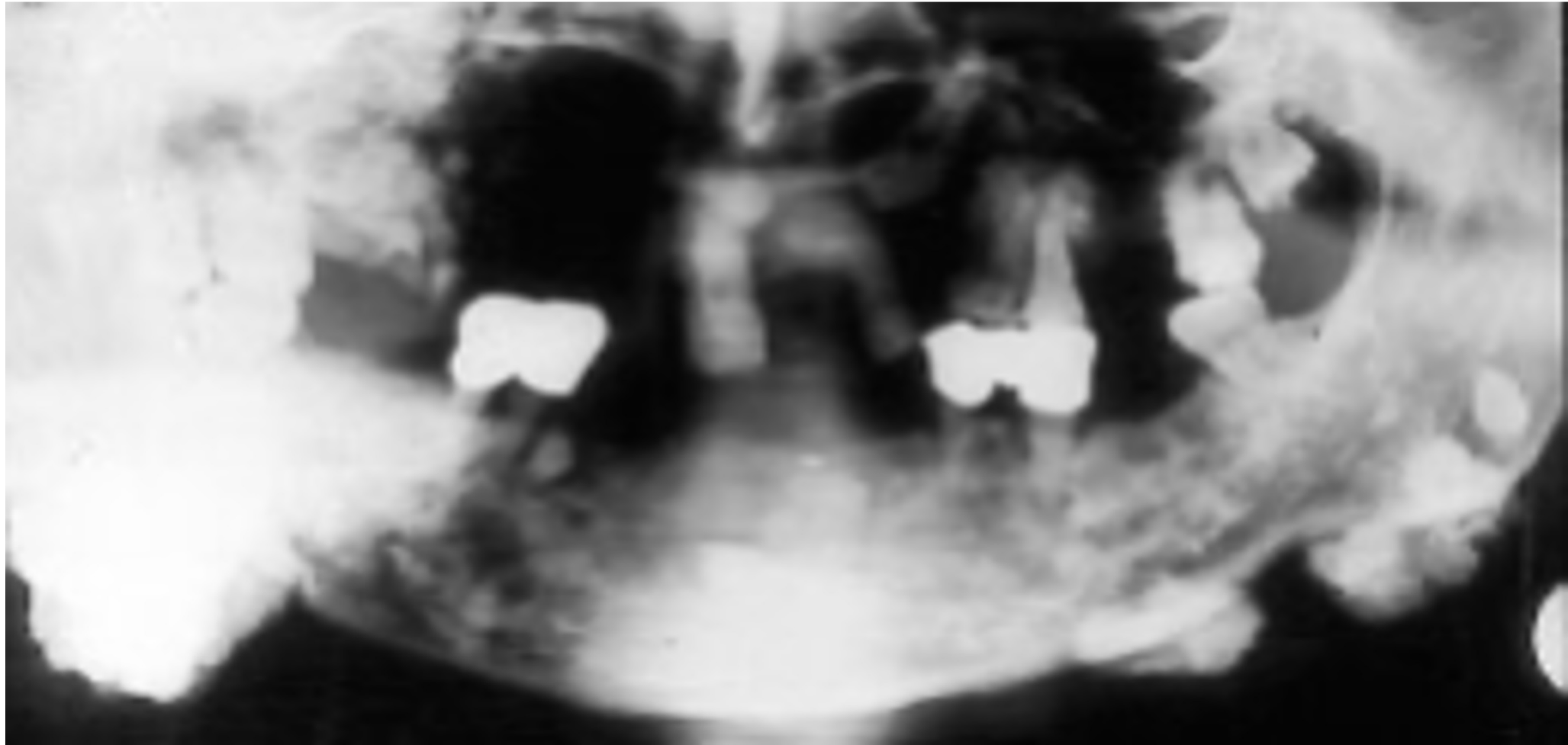
- Epiphysis of long bones; 20-40 yrs; cortical lesions

- Ewing sarcoma (tumor)

- Diaphysis and metaphysis; 10-20 yrs; medullary lesions;
small round cells; t(11;22); FLI-EWS gene fusion



Osteomas



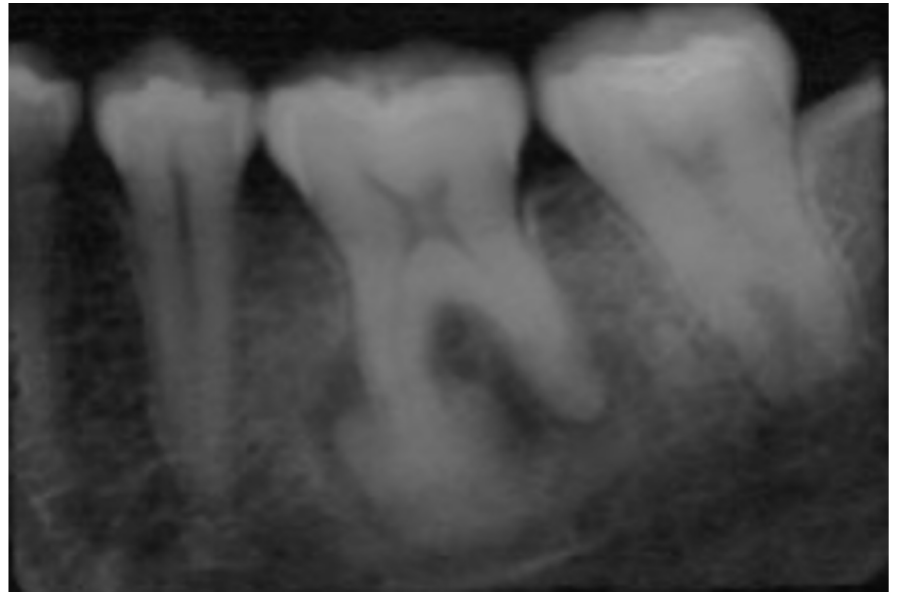
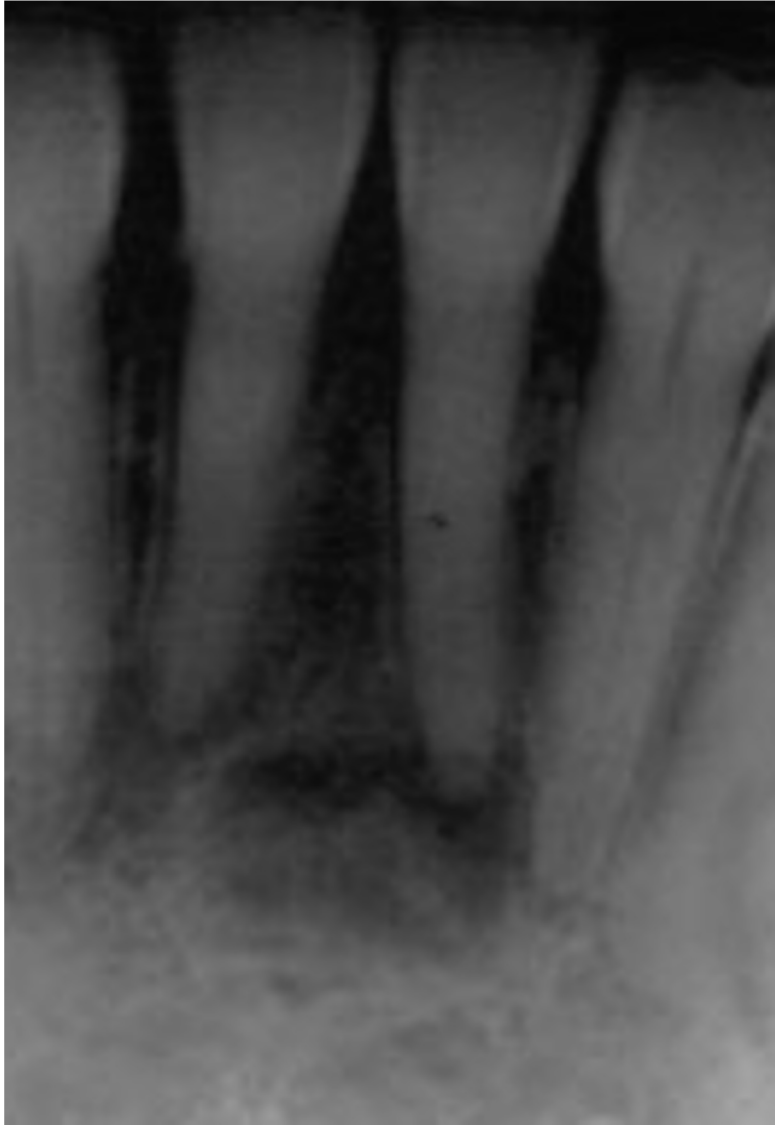Cemento-Osseous Dysplasia

Periapical cemento-osseous dysplasia

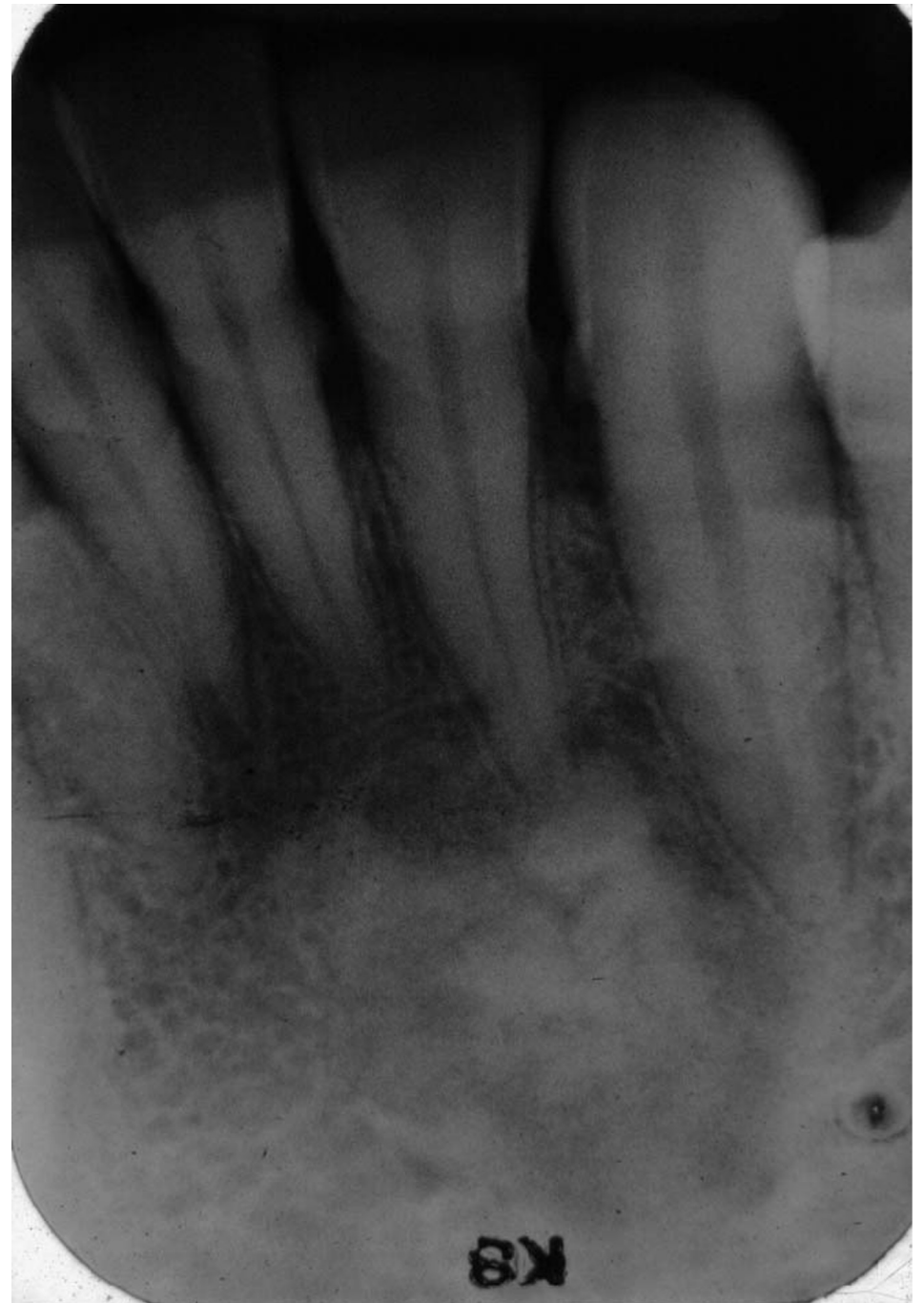- Periapical region of anterior mandible
- Middle-aged African-American women
- 30-50yrs
- Associated teeth are vital

Radiographic Features

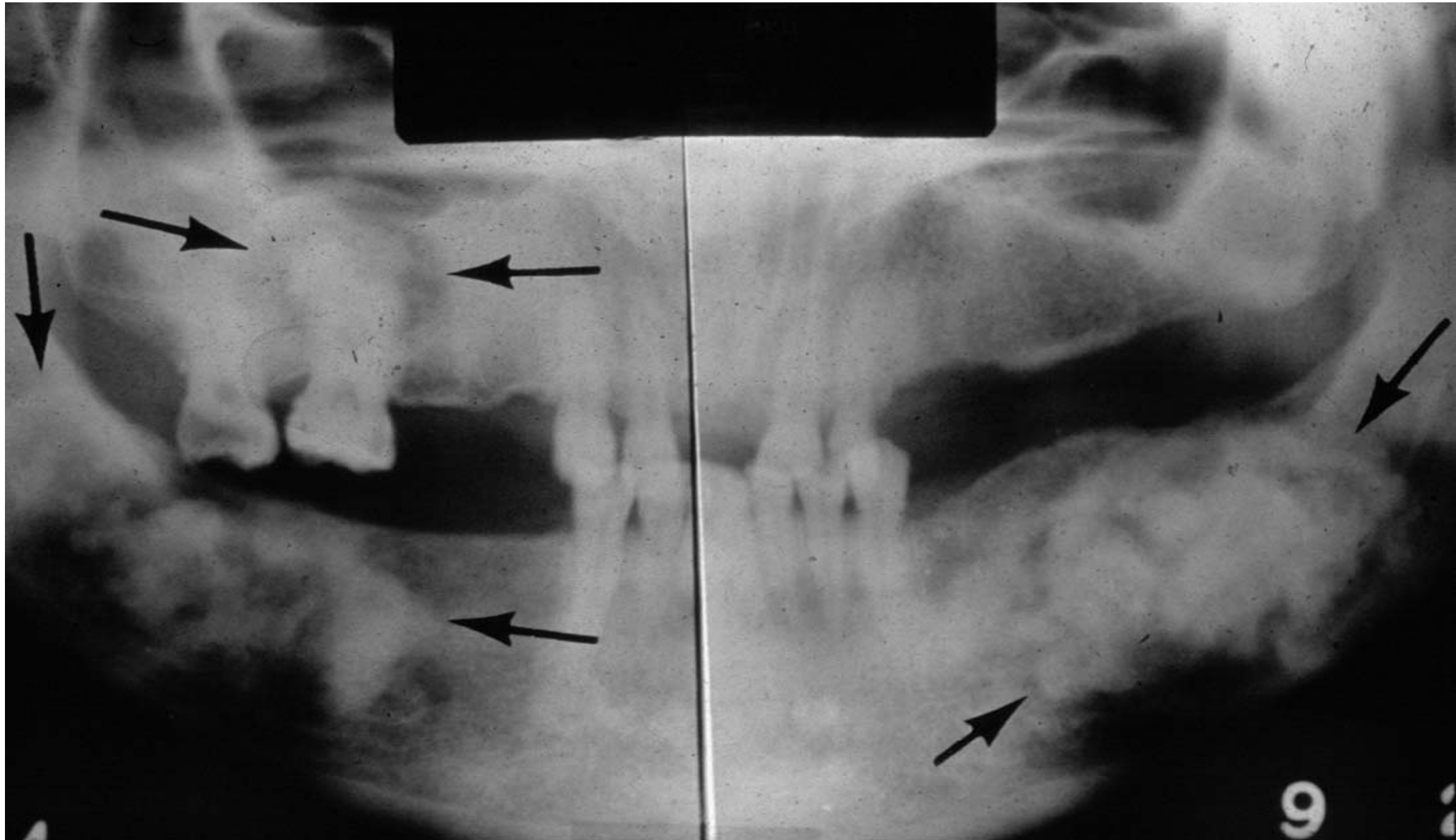
- Early lesions: Periapical circumscribed radiolucencies
DD: Periapical granuloma and cyst
- Late lesions: Linear pattern of radiolucency
- Mature lesions: Mixed radiolucent-radiopaque



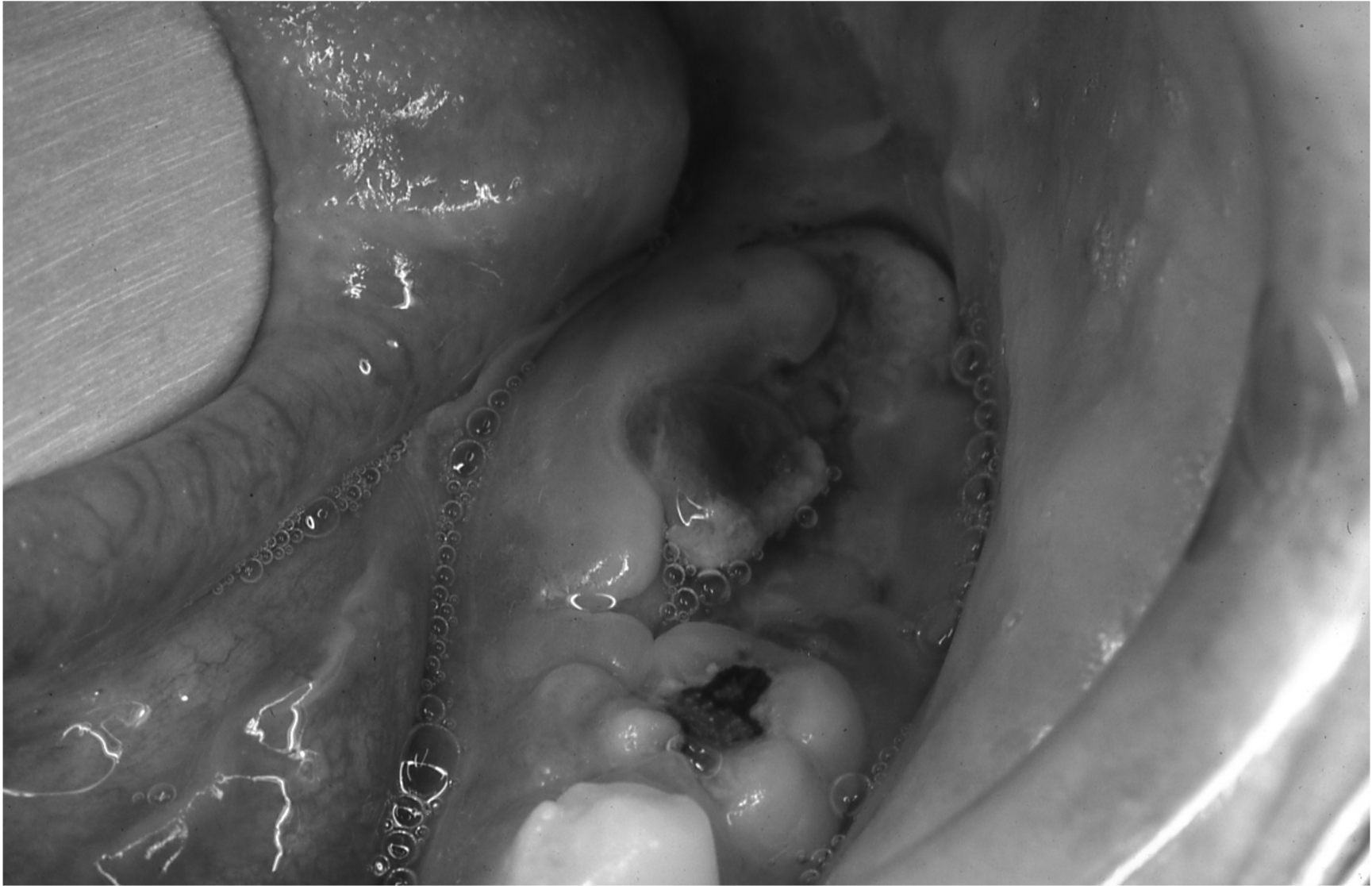Periapical Cemental Dysplasia



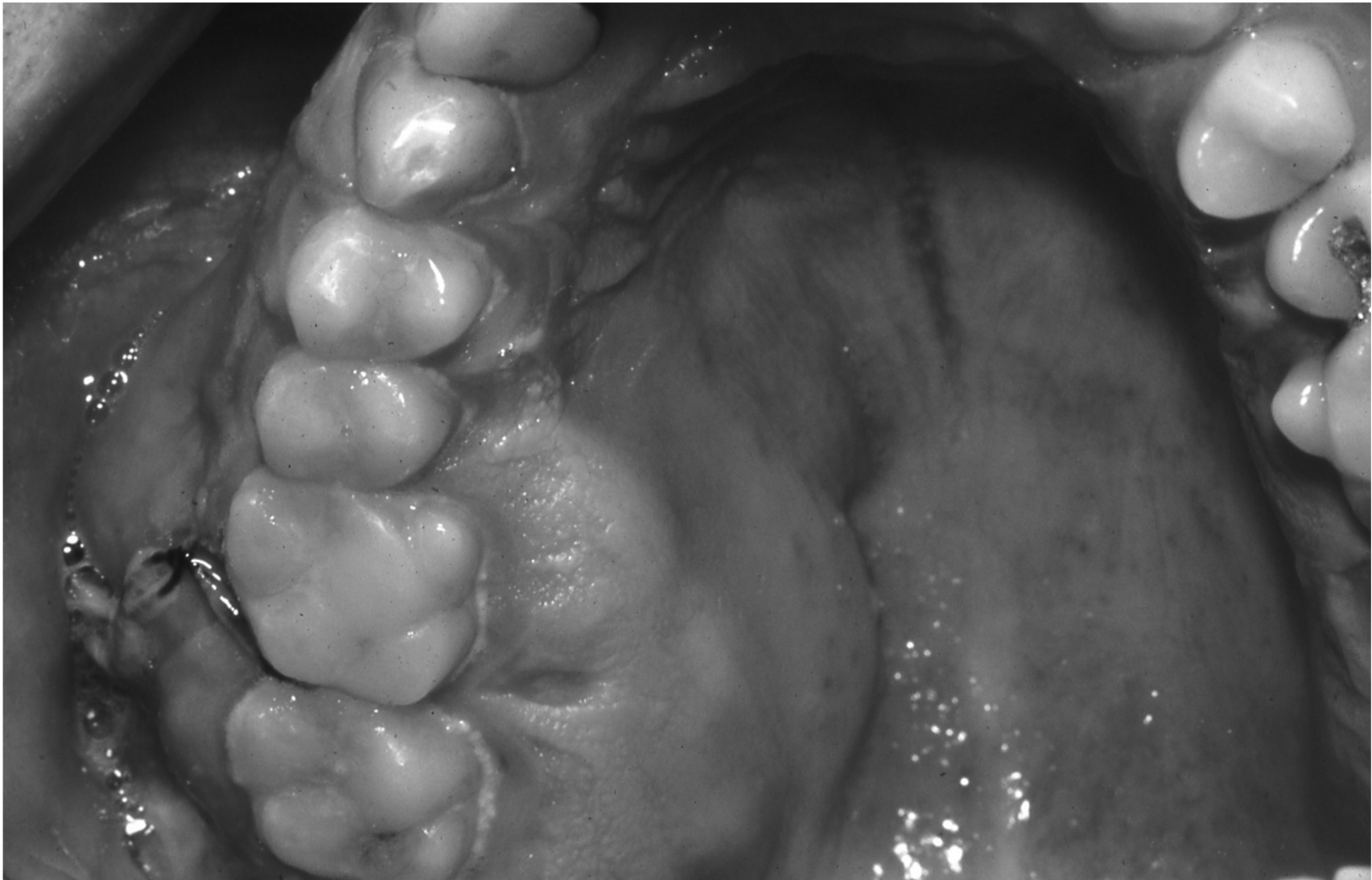
Florid Osseous Dysplasia



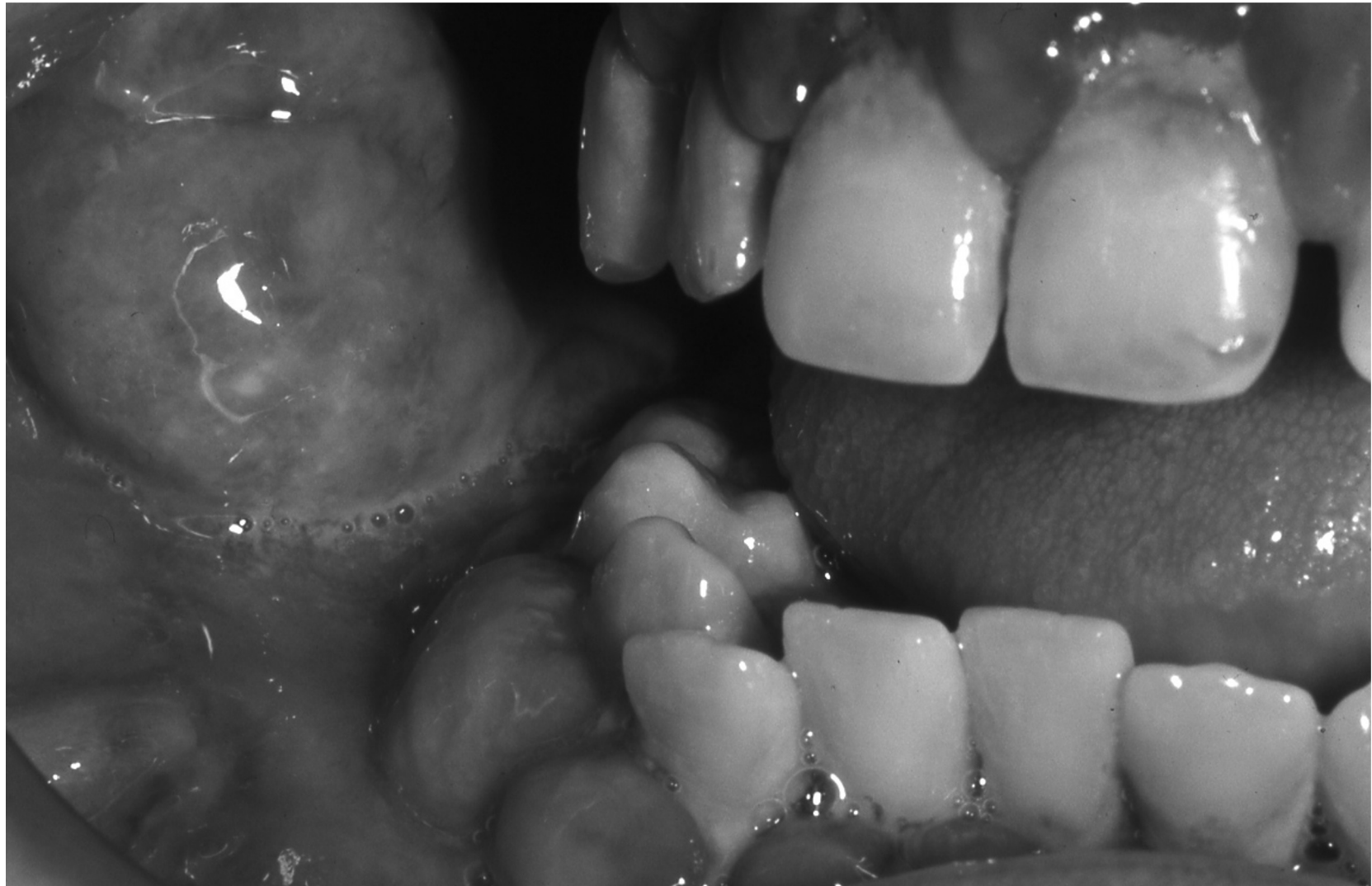Osteosarcoma



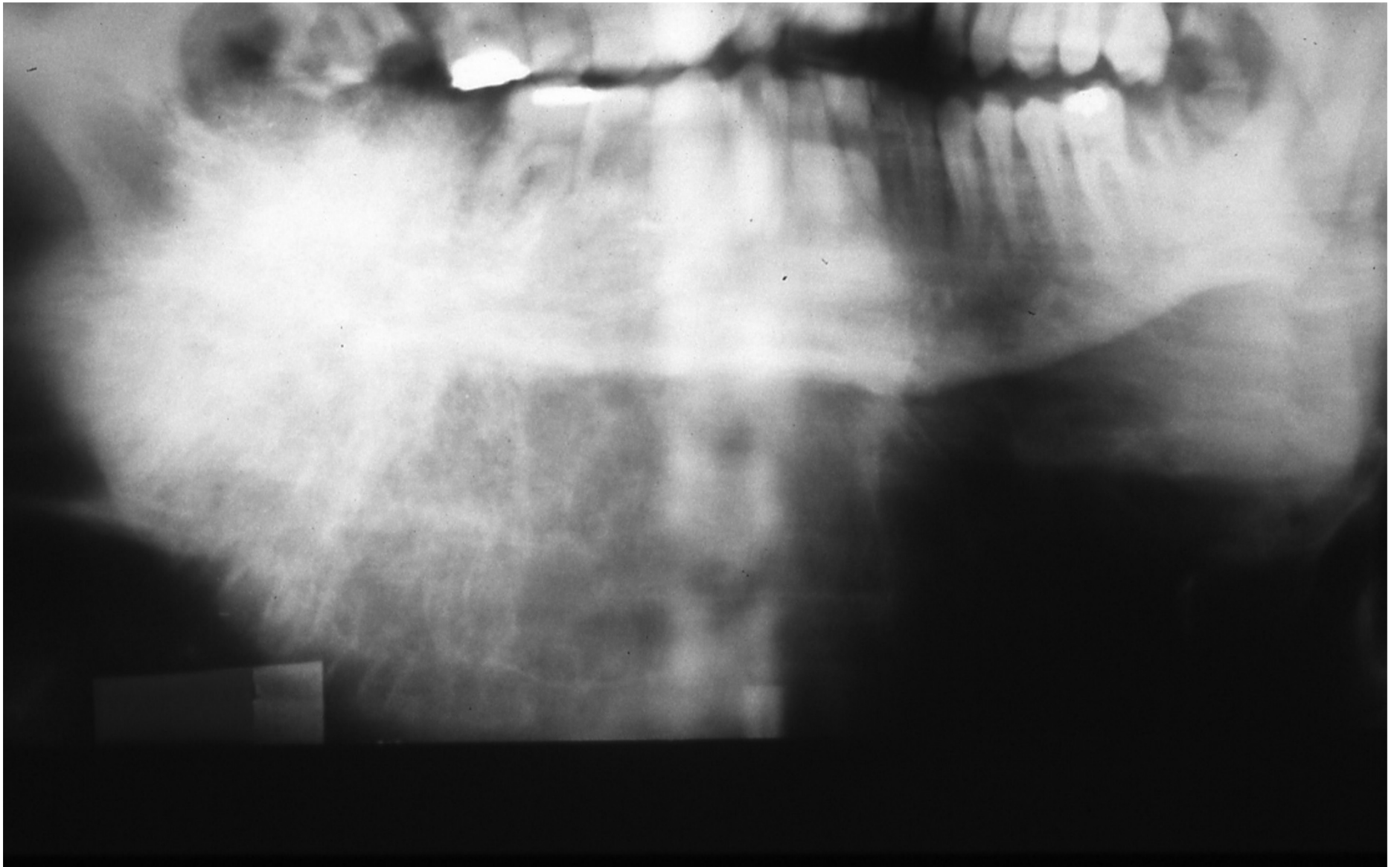
Osteosarcoma



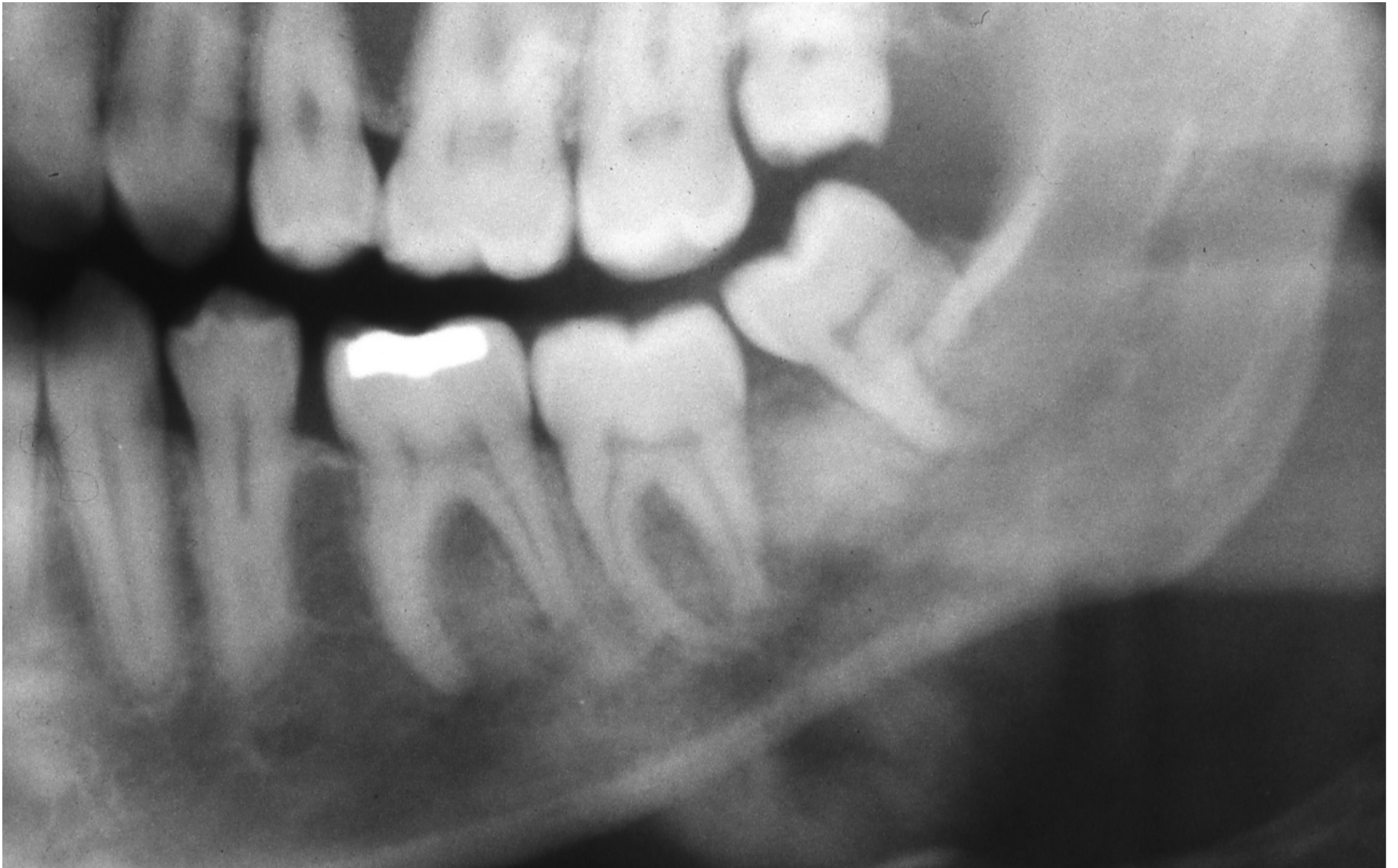
Osteosarcoma



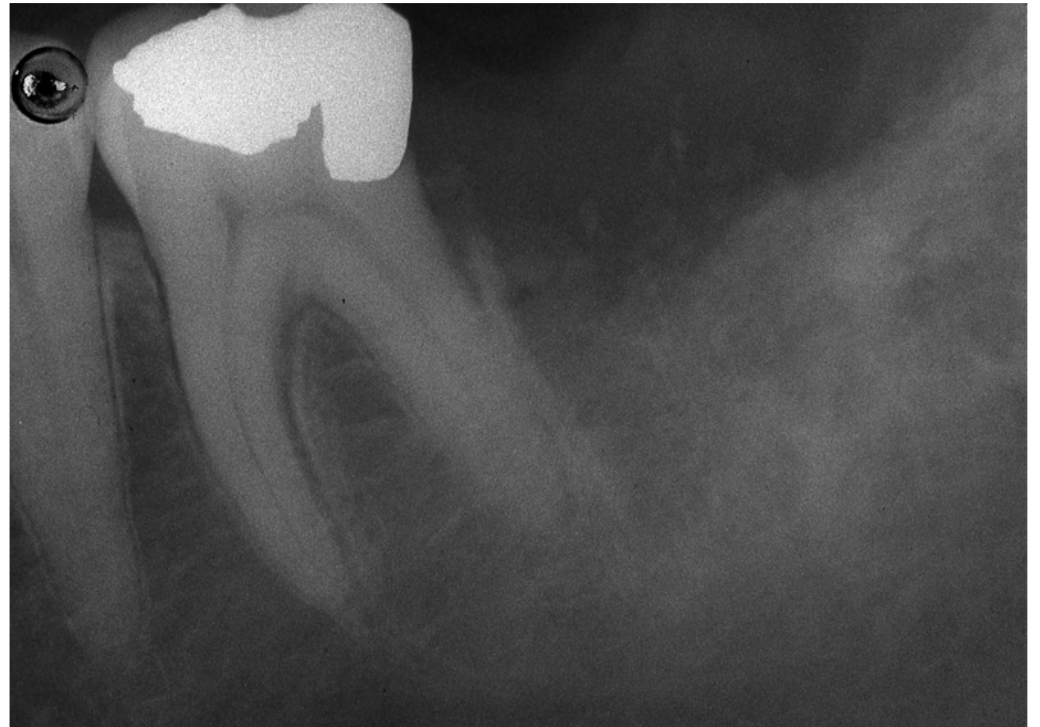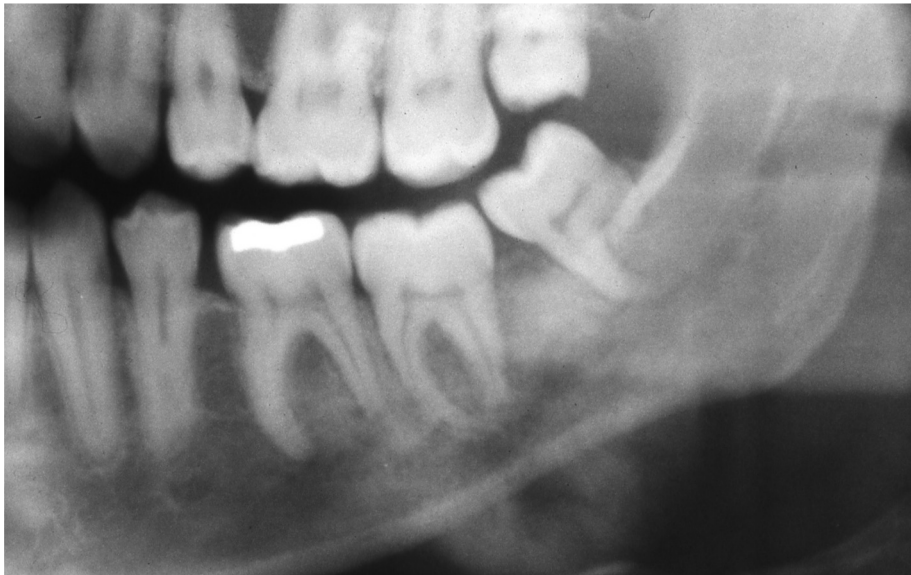Osteosarcoma



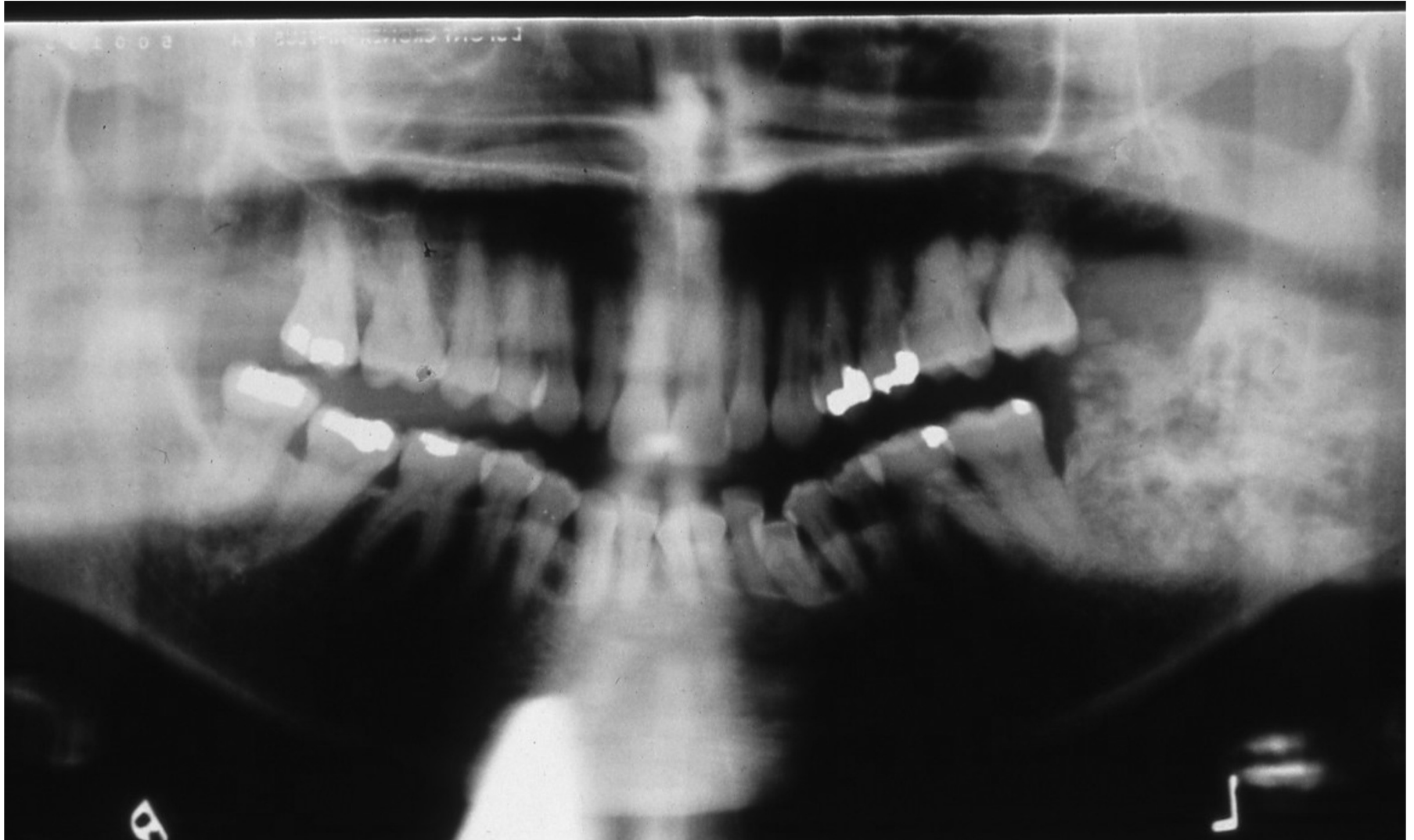Osteosarcoma



Osteosarcoma



Chondrosarcoma



Metastatic Tumors of the Jaws

Most common form of cancer involving bone

Breast and prostate carcinomas are most common

>80% of jaw metastasis occurs in mandible

Variety of symptoms: pain, swelling, loose teeth, paresthesia

Metastasis found in nonhealing extraction

Site from which tooth was removed for local pain or mobility

Irregular radiolucency (moth eaten appearance)

Prognosis is poor; most patients die within a year



